



u^b

**UNIVERSITÄT
BERN**

CLINICAL ASSESSEMENT OF THE SHOULDER GIRDLE

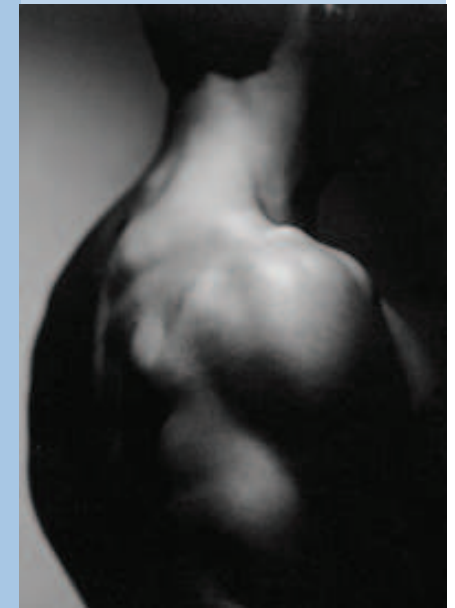
Remy Flückiger, MD

Shoulder, Elbow & Orthopedic Sports Medicine

Department of Orthopedic Surgery and Traumatology

University of Berne, Switzerland

Remy.flueckiger@insel.ch

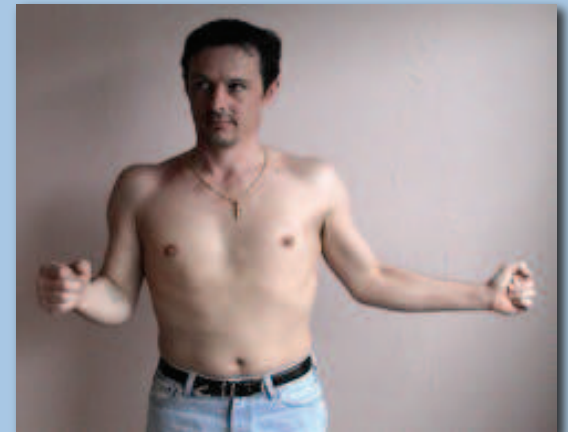


INTRODUCTION

- **Personal history**
- **Clinical exam**

SUSPECTED DIAGNOSIS

- **Complementary investigations to rule out differential diagnosis**



ANAMNESIS

Reasons for consultation:

- Pain +++
- Instability +++



In sport traumatology

- Loss of function
(Pseudoparalysis versus Stiffness)

ANAMNESIS

Pain characteristics:

Intensity: VAS (/10)

Location (one FINGER +++):

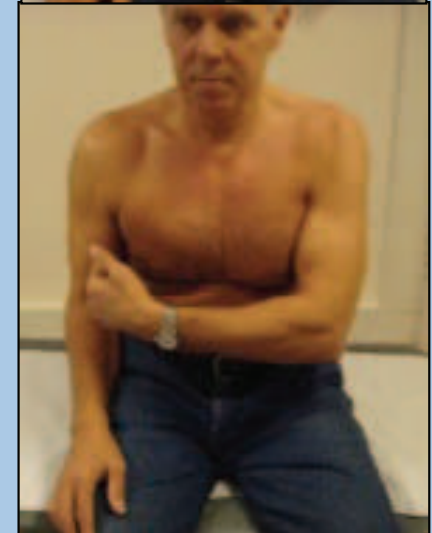
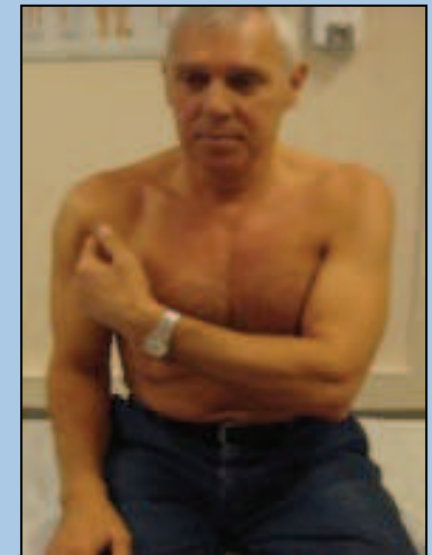
Irradiation:

Into the arm, hand, neck

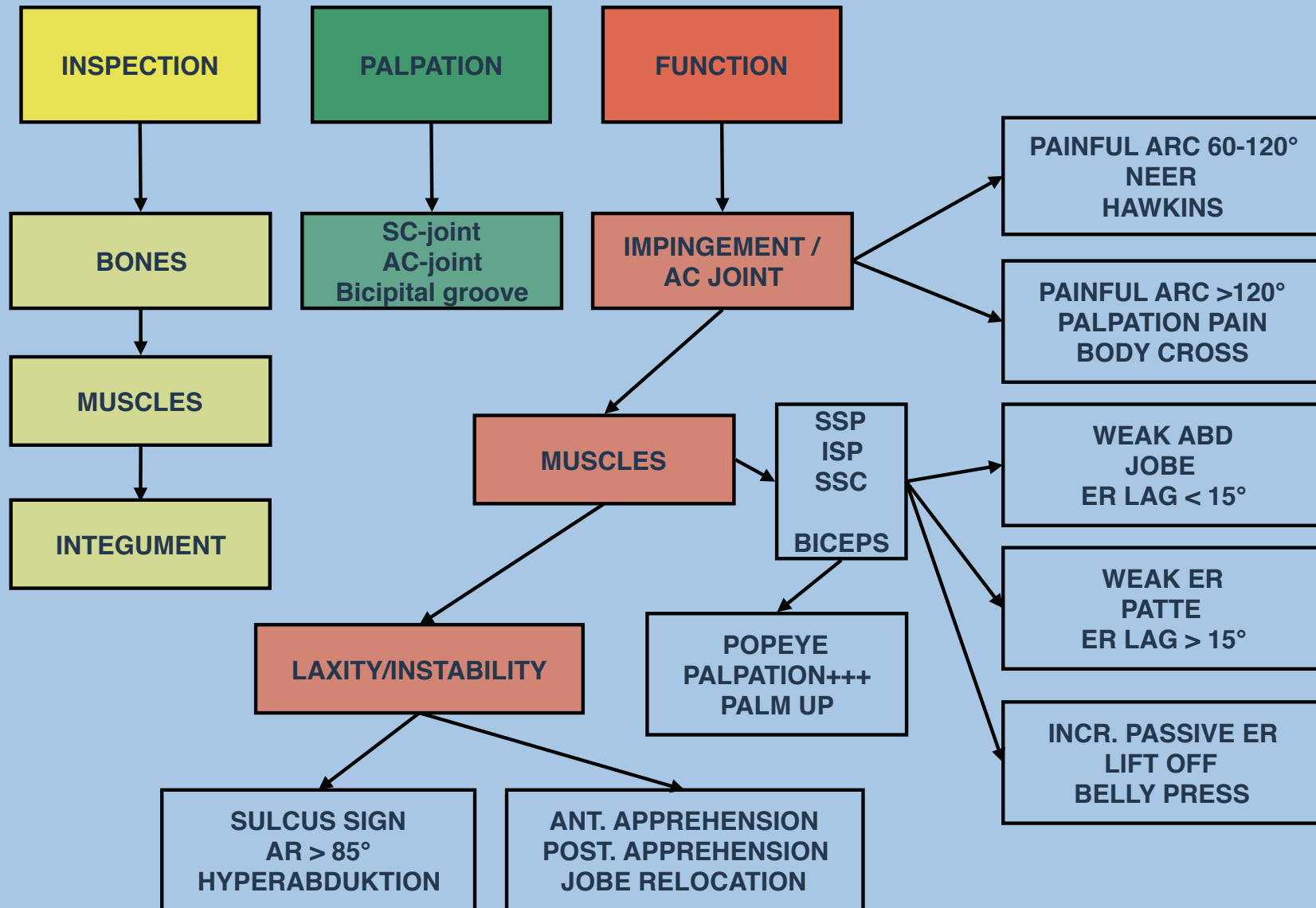
Night pain?

Relieving/exacerbating factors?

Motion? Sport's level and discipline?



RULE OF „3“

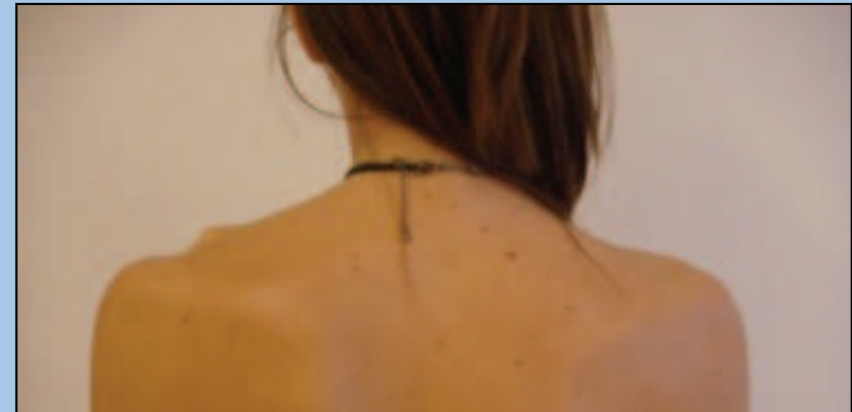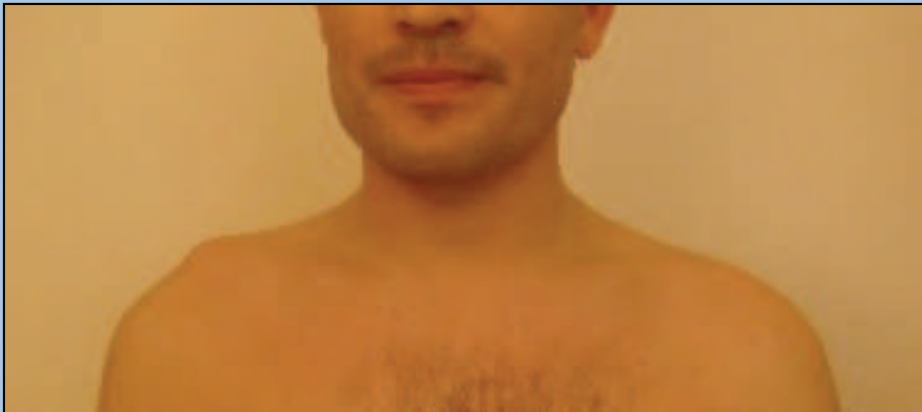


BONES


INSPECTION

Deformation of bony landmarks

- Distal clavicle +++
- Acromion

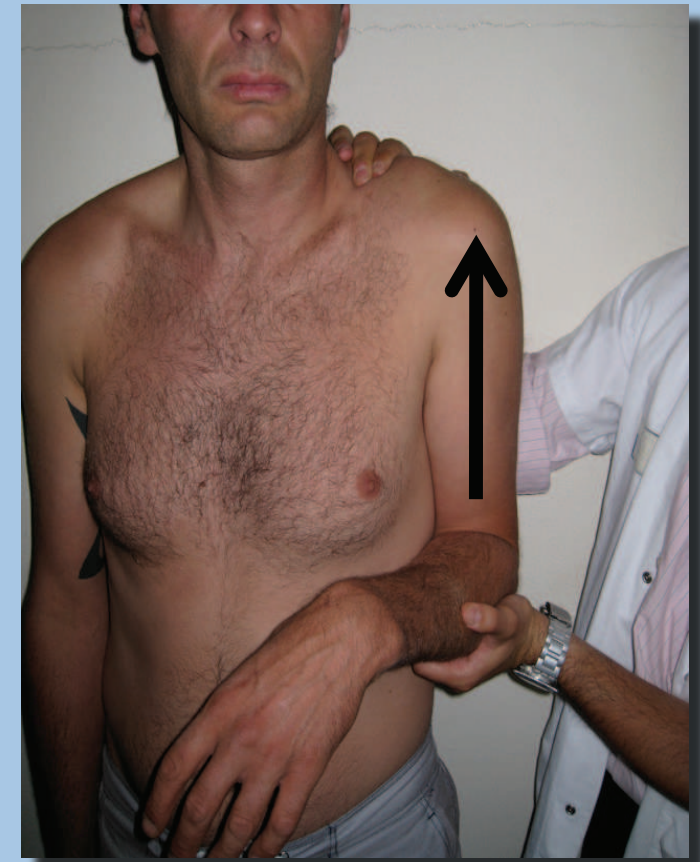
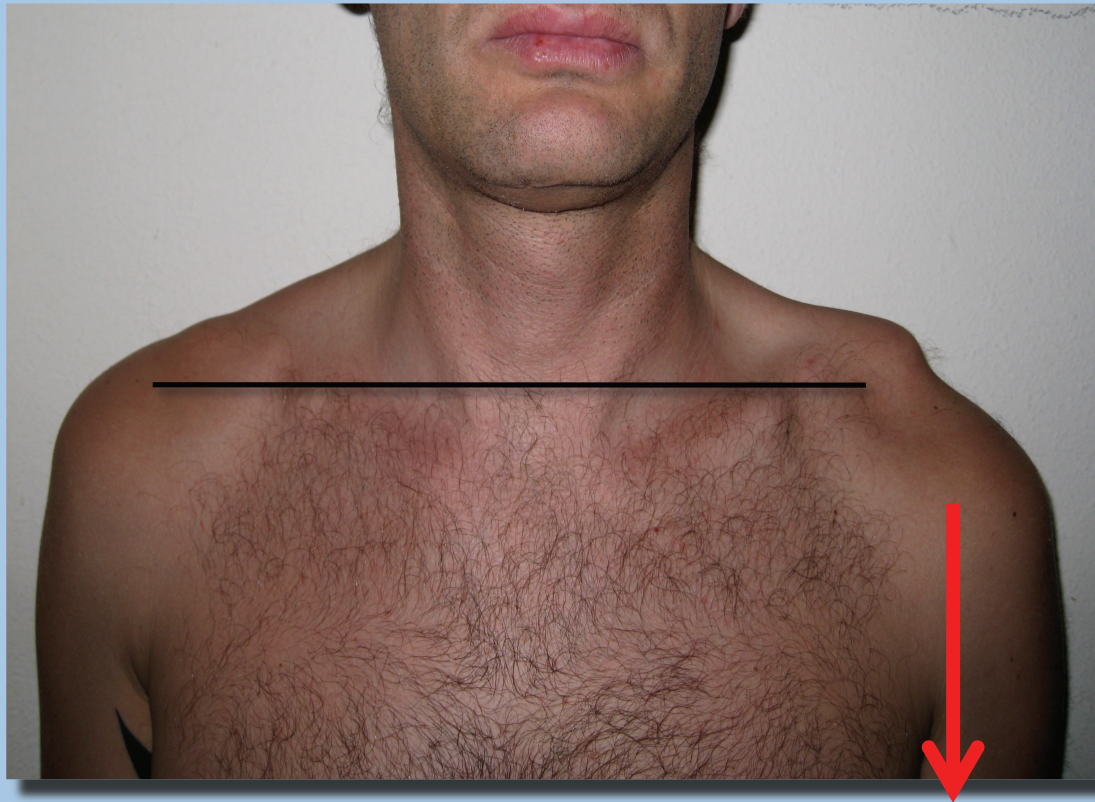

Acromio-clavicular Lesion



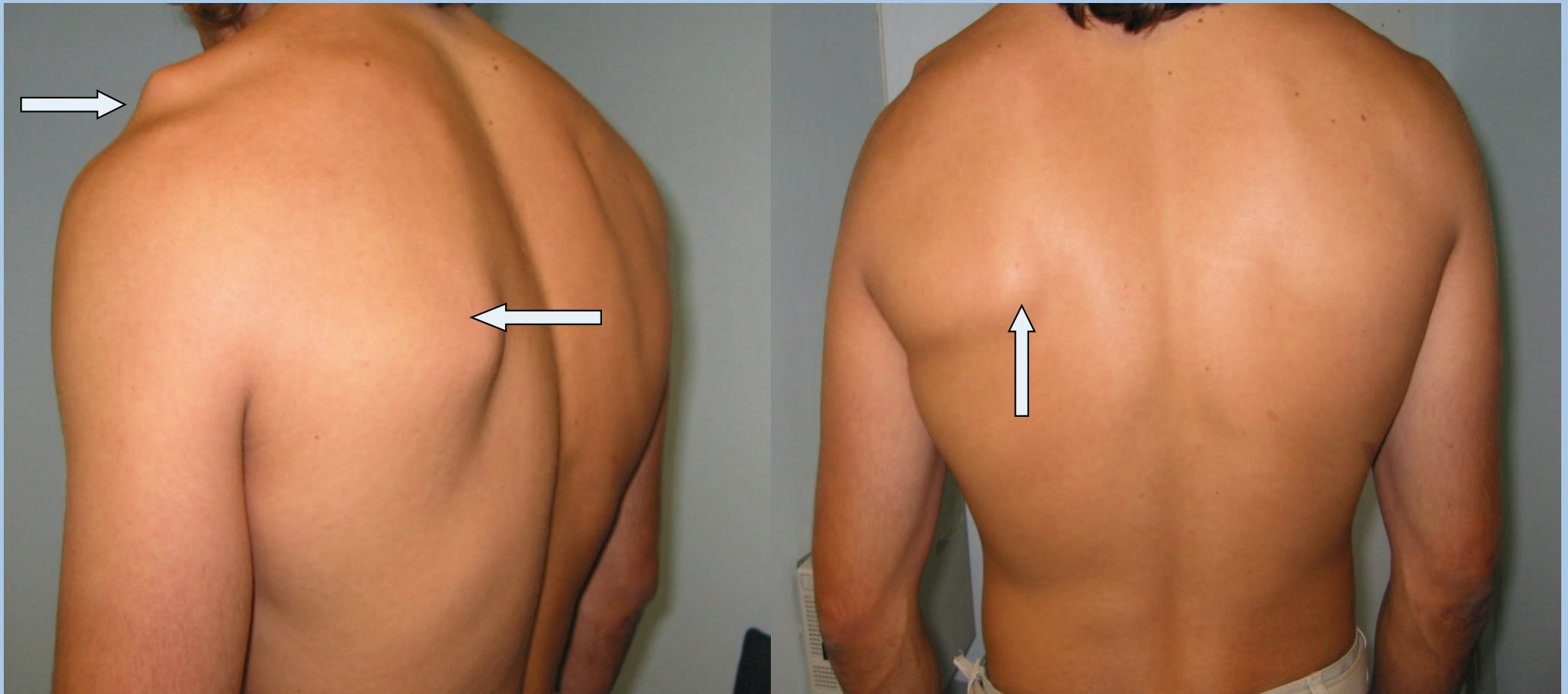
Rx

AC-JOINT DISLOCATION: VERTICAL INSTABILITY



**Trapezoid & conoid ligament
= suspensory ligaments of the shoulder girdle**

ROTATORY INSTABILITY OF THE SCAPULA

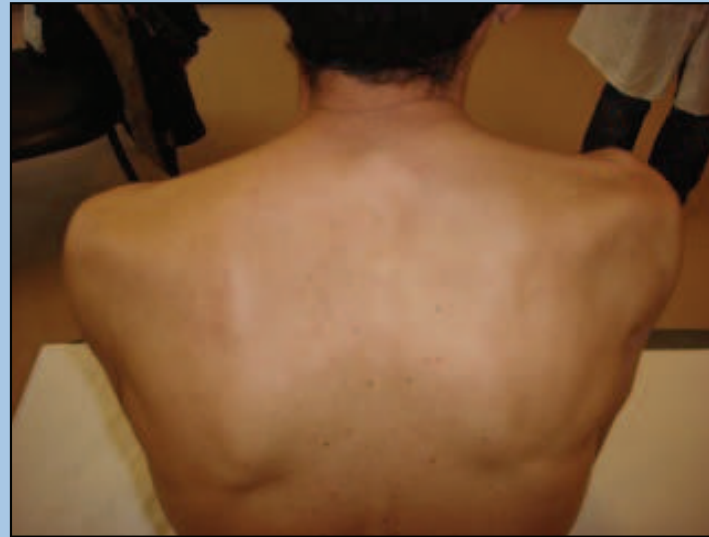
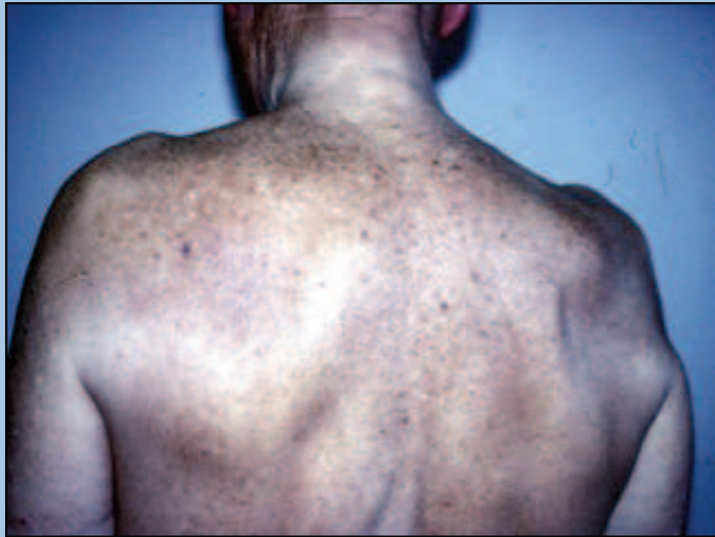

Courtesy of J. de Beer

MUSCLES

Muscular atrophies

- Fossa SSP/ISP
- Deltoideus

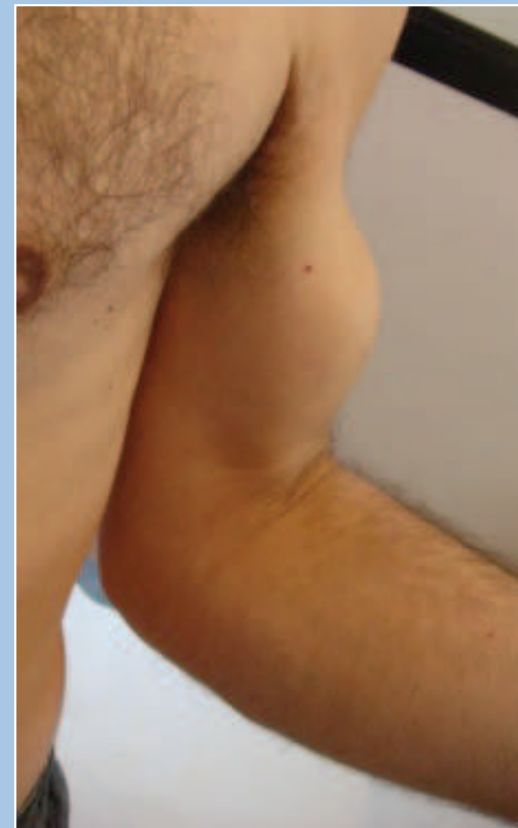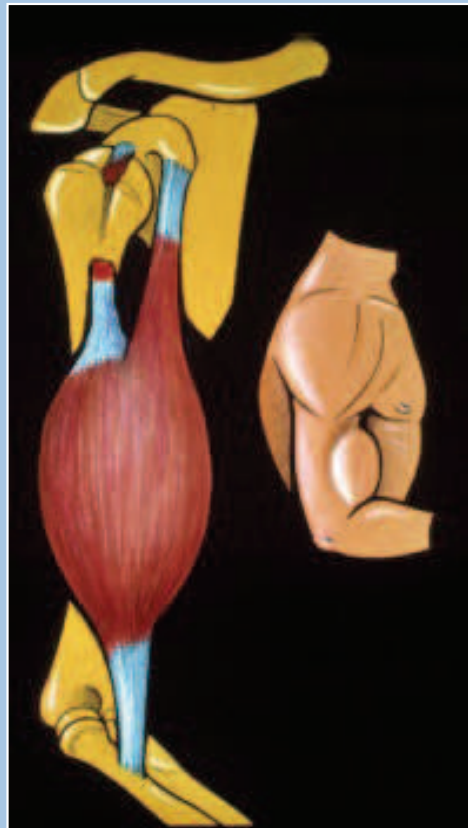


BICEPS

INSPECTION

Popeye Sign

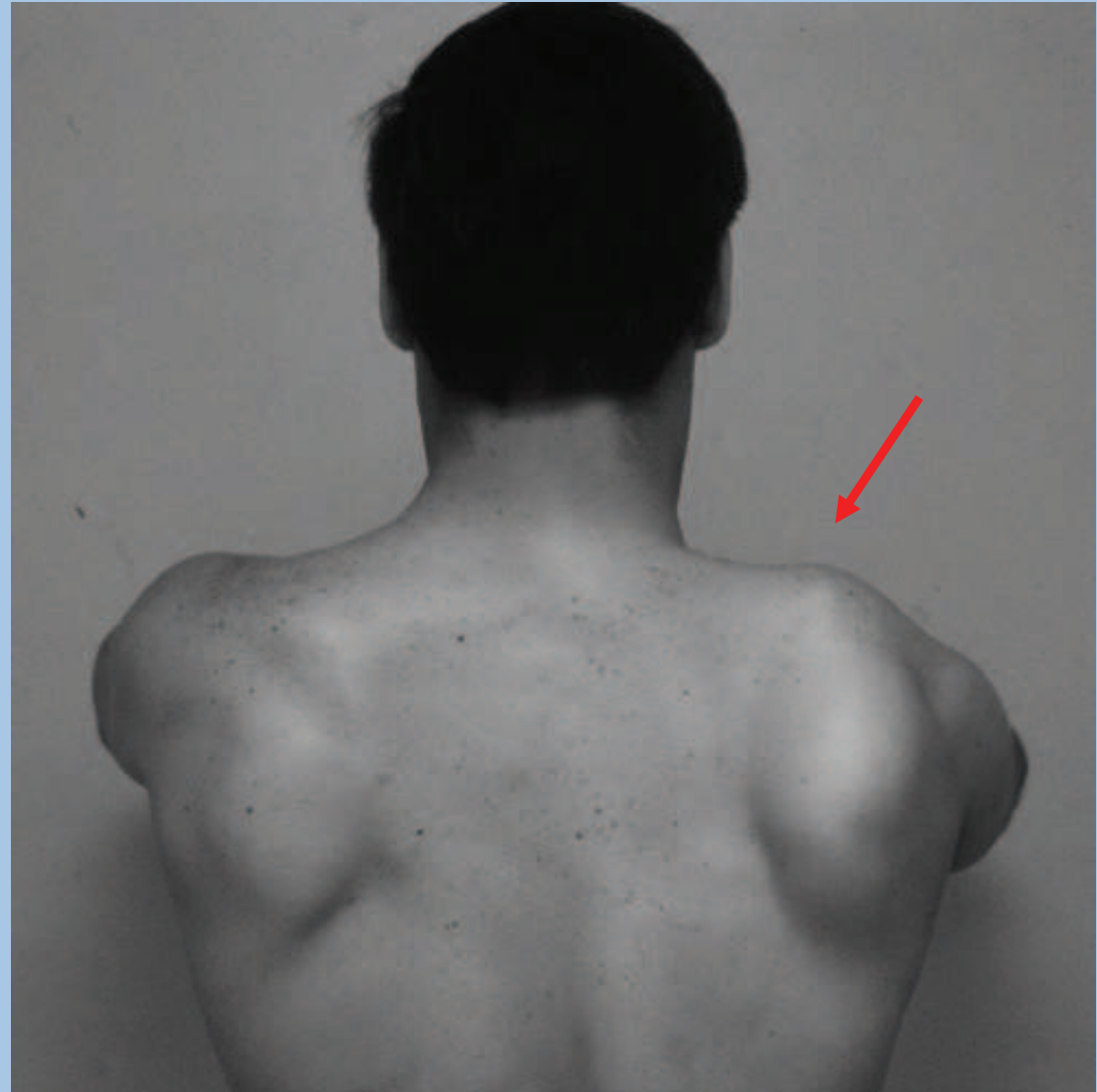- Proximal lesion of the LHB



NEURAL LESIONS

INSPECTION

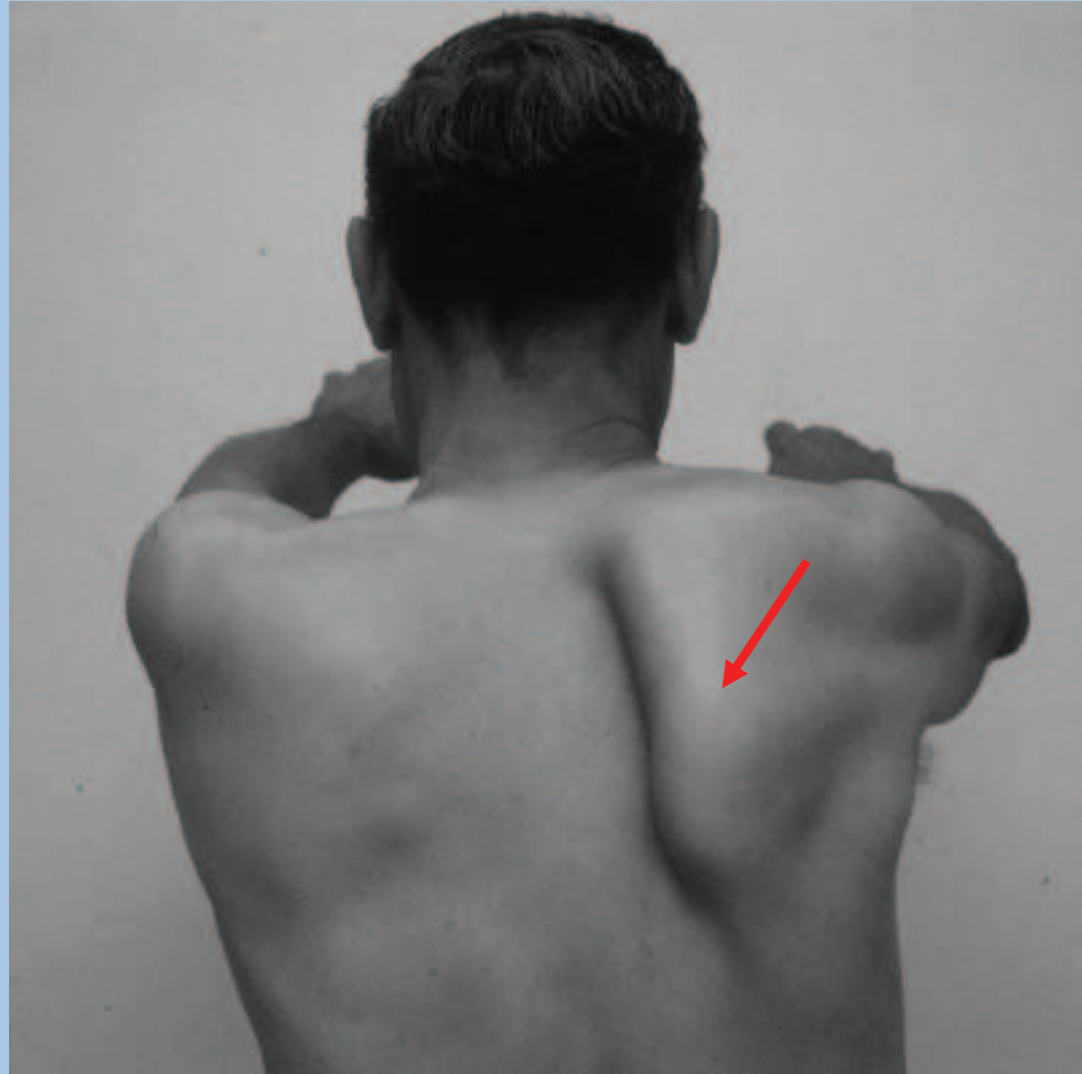- N. accessorius
- N. thorac. long.
- N. supraskapul.
- N. axillaris



NEURAL LESIONS

INSPECTION

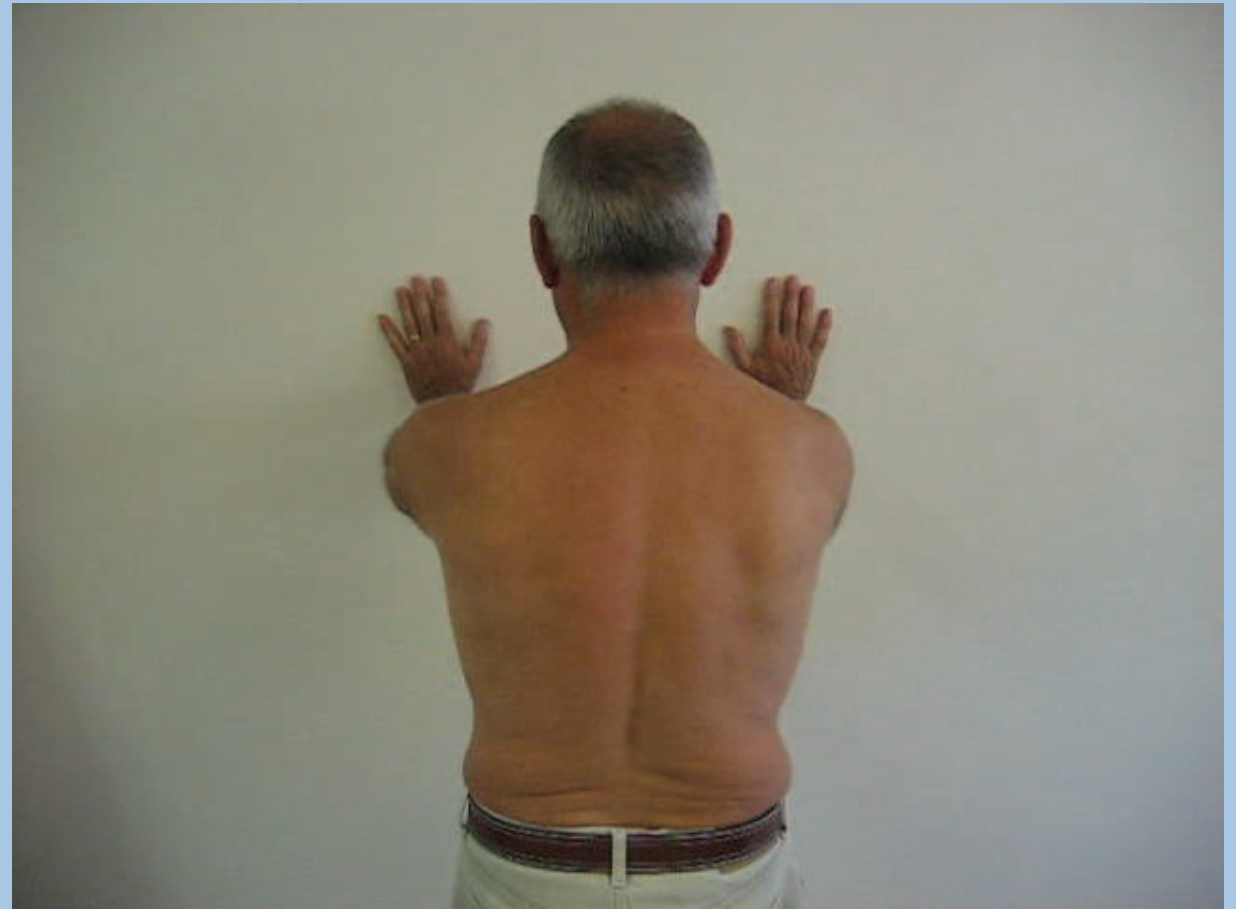- N. accessorius
- N. thorac. long.
- N. supraskapul.
- N. axillaris



NEURAL LESIONS

INSPECTION

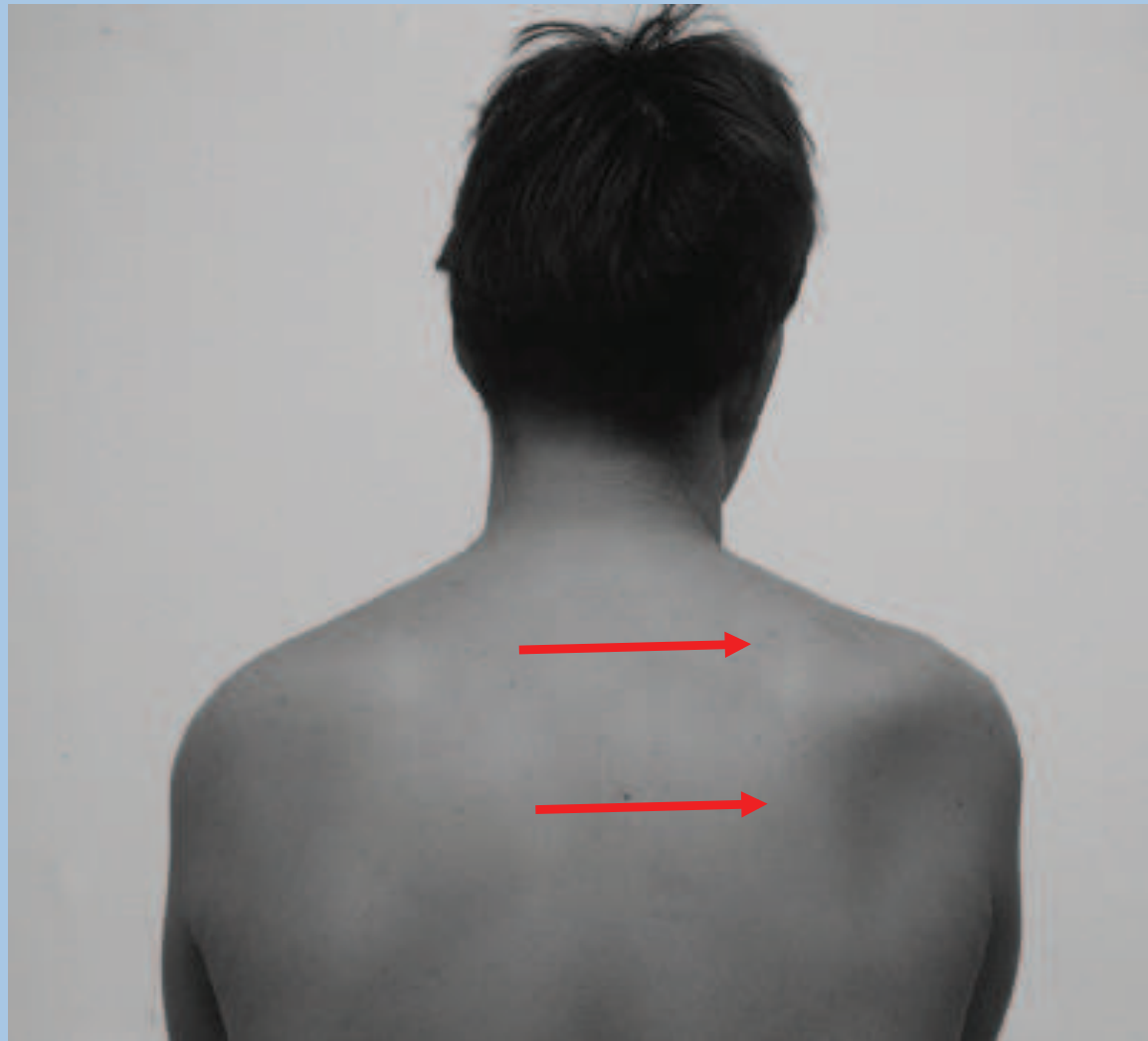- N. accessorius
- N. thorac. long.
- N. supraskapul.
- N. axillaris



NEURAL LESIONS

INSPECTION

- N. accessorius
- N. thorac. long.
- N. supraskapul.
- N. axillaris



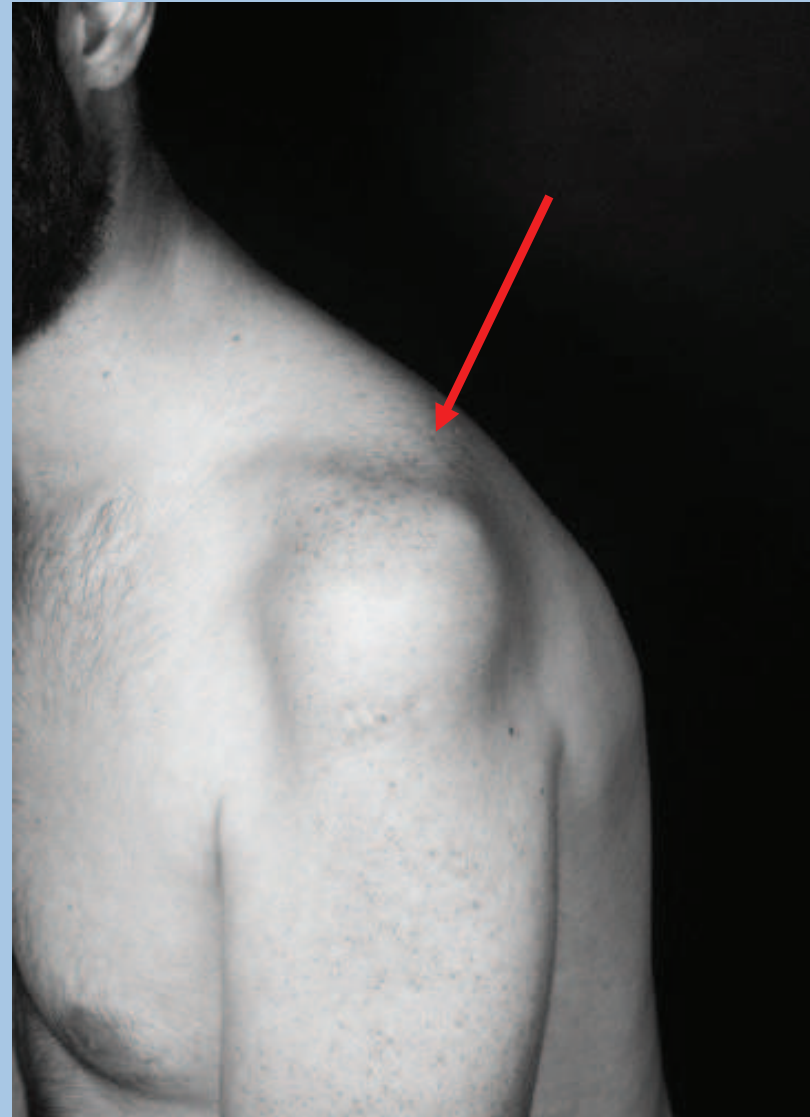NEURAL LESIONS

INSPECTION

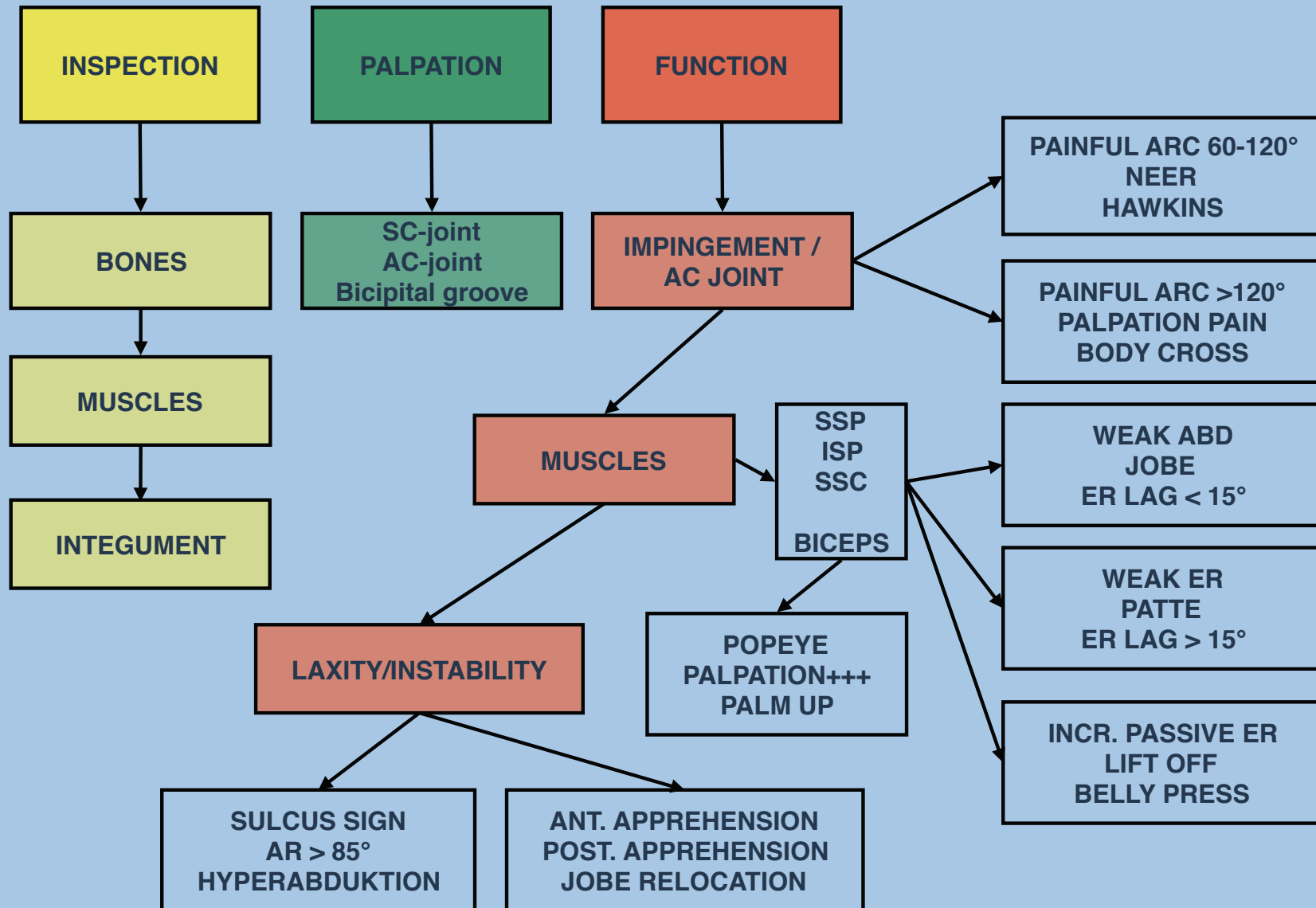
u^b

UNIVERSITÄT
BERN

- N. accessorius
- N. thorac. long.
- N. supraskapul.
- N. axillaris



RULE OF „3“

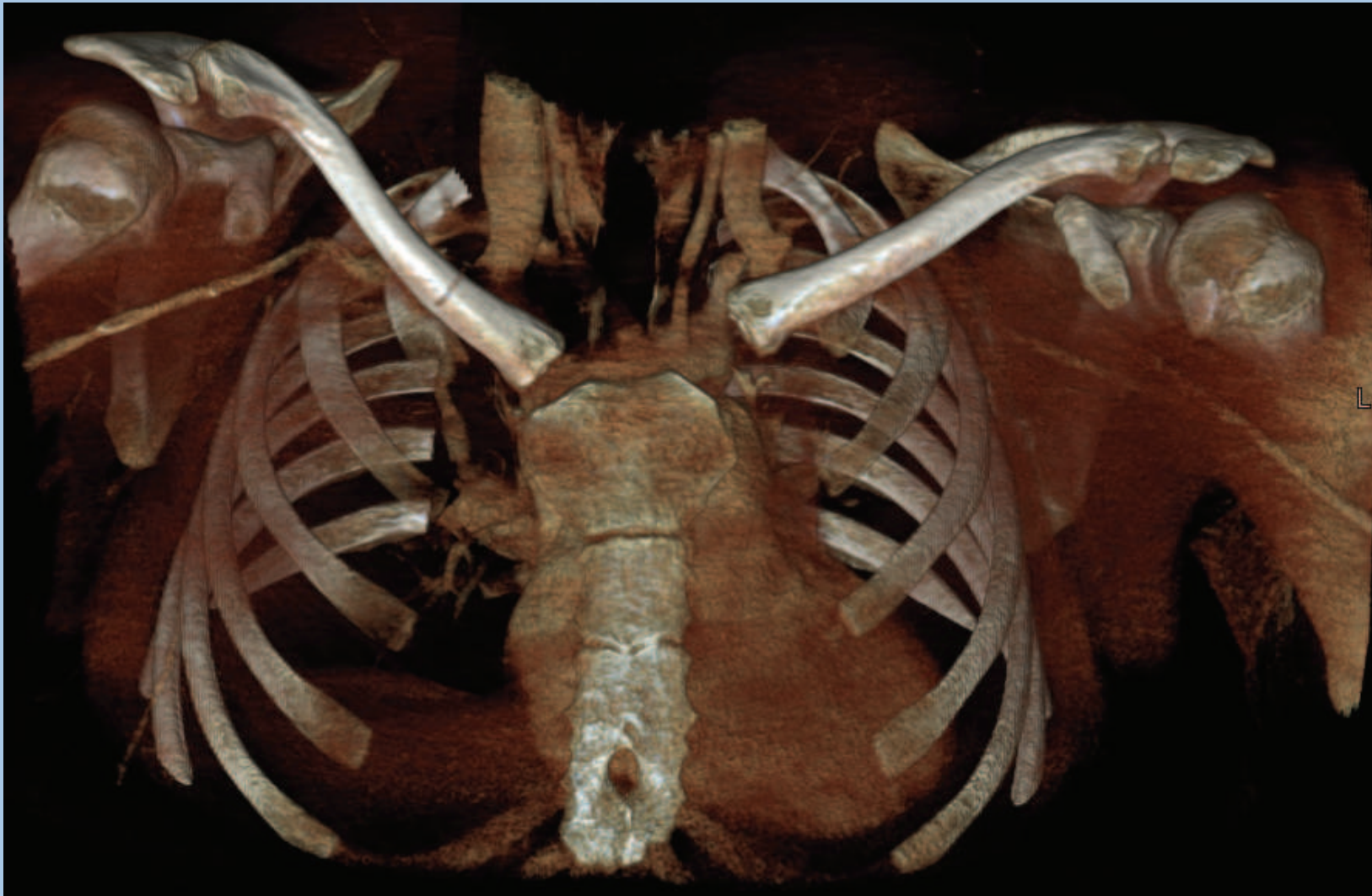


SC-JOINT

PALPATION

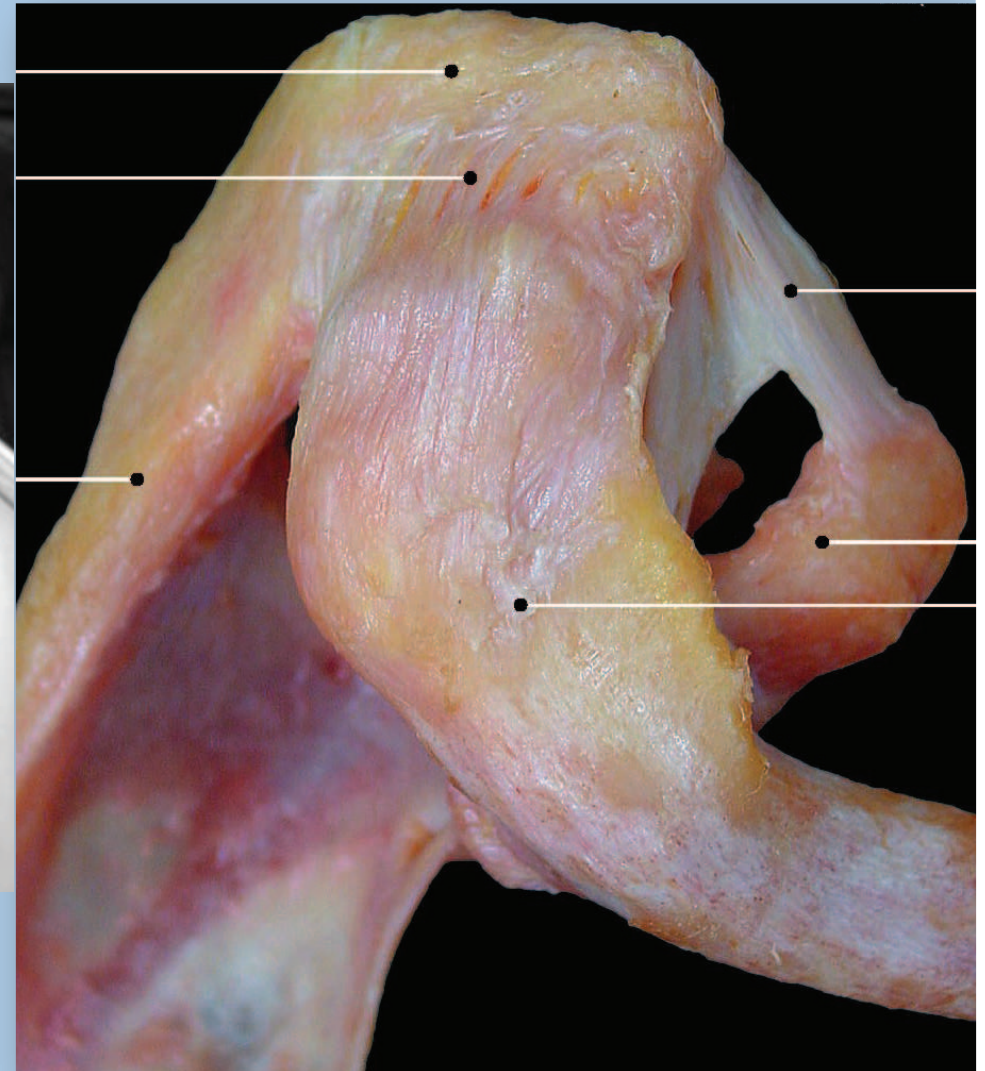
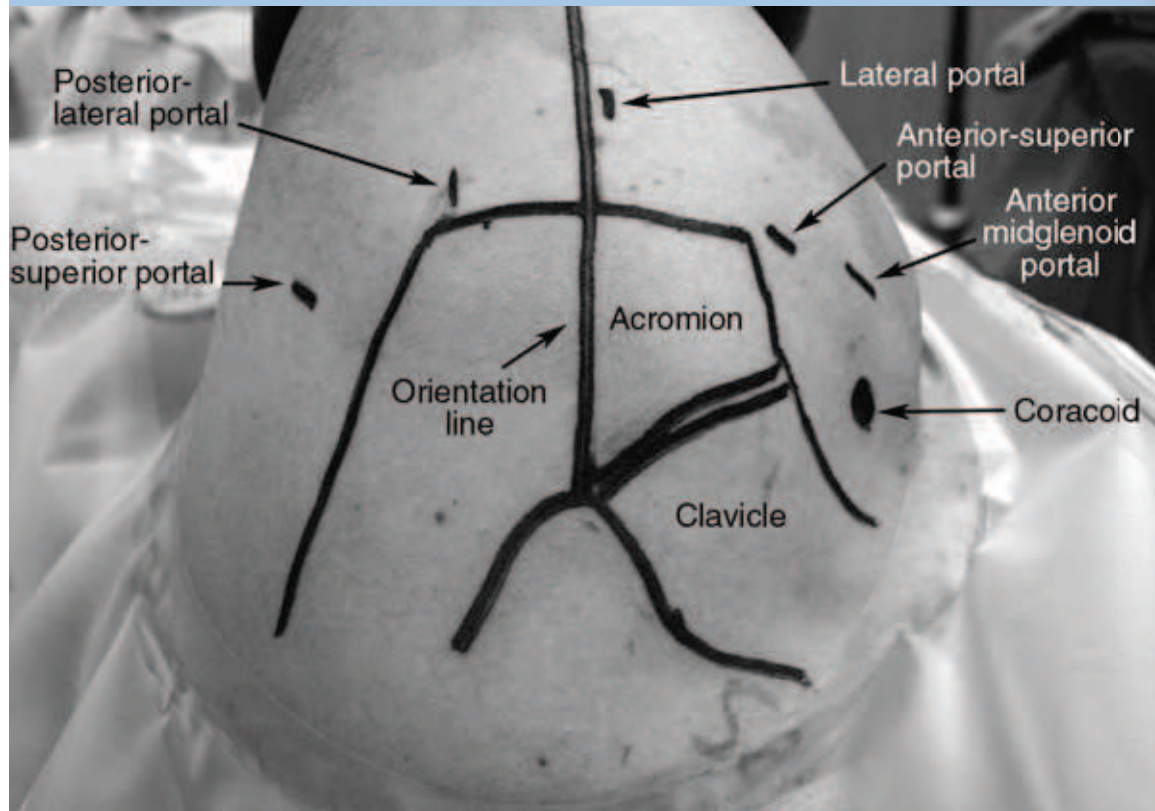
u^b

UNIVERSITÄT
BERN



BONY LANDMARKS

PALPATION



RANG OF MOTION (ROM)

FUNCTION

JOINT FUNCTION


- Global versus glenohumeral
- Active versus passive

LAG-Signs: Difference between active and passive ROM

LOSS OF ROM

FUNCTION

active



passive normal

passive limited



Damaged Motor

Stiffness

LOSS OF ACTIVE ROM

FUNCTION

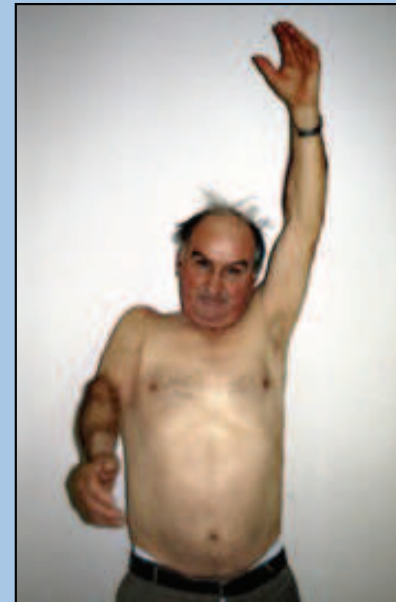
- Critical for decision making!
- Two elementary clinical situations

passive normal

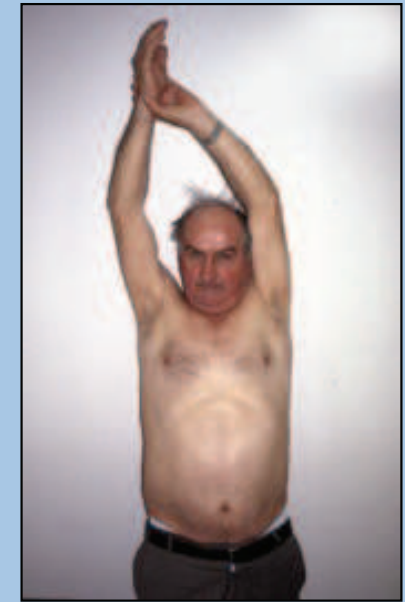
(Pseudo-)Paralysis

DD: - RCT

- Neural lesion



⊗ active



Passive free

LOSS OF ACTIVE ROM

FUNCTION

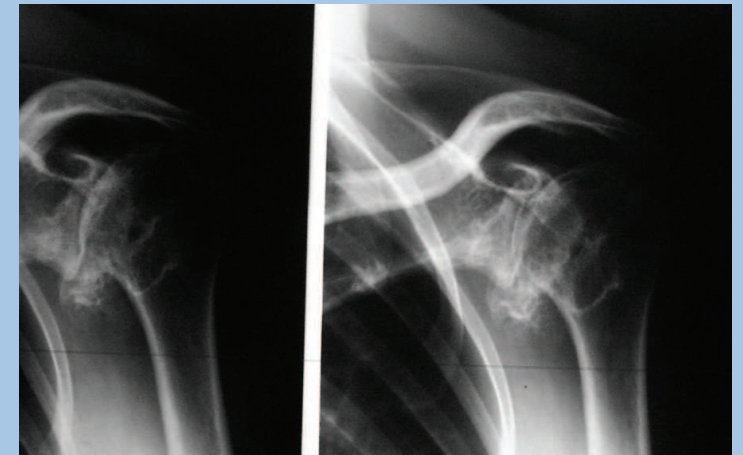
- **Critical for decision making!**
- **Two elementary clinical situations**

Passive and active limitation



Stiffness

DD: - Capsulitis (Frozen Shoulder)
- Osteoarthritis

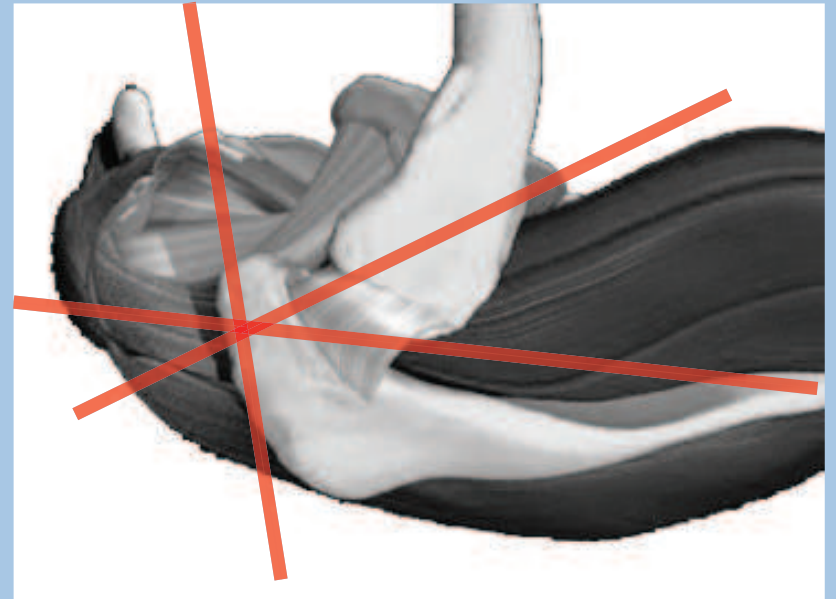


DEFINITIONS

FUNCTION

FUNCTIONAL PLAINS:

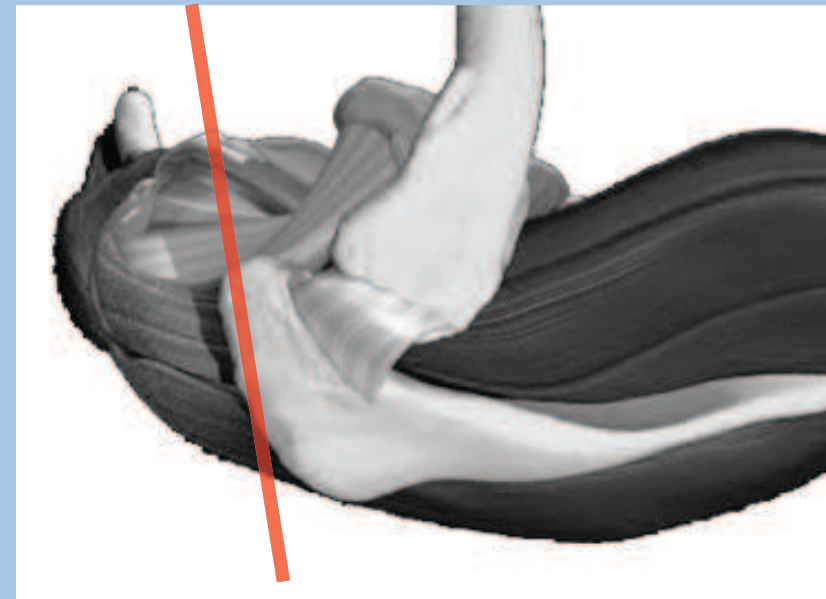
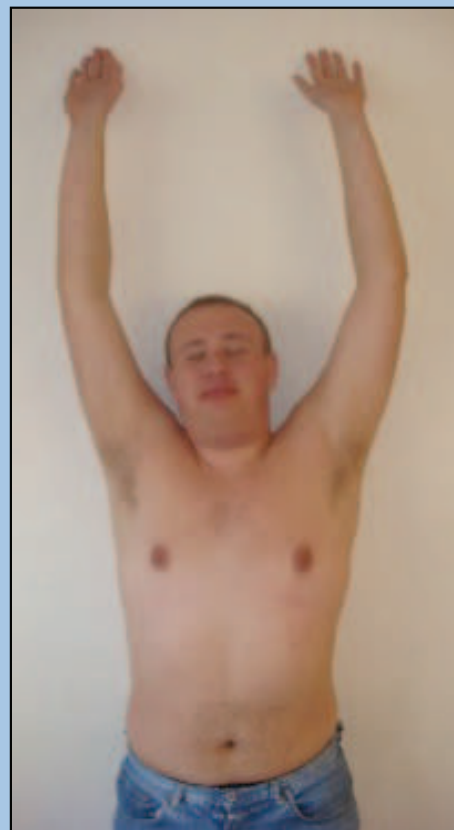
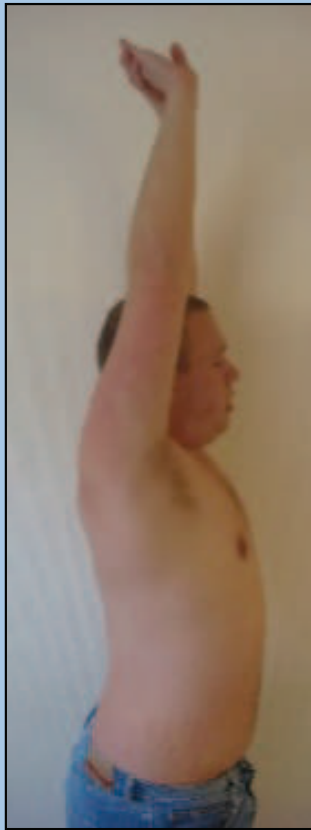- Flexion (sagittal plain)
- Elevation (scapular plain)
- Abduction (coronar plain)
- External rotation (ER)
- Internal rotation (IR)



FLEXION (Anteversion)

FUNCTION

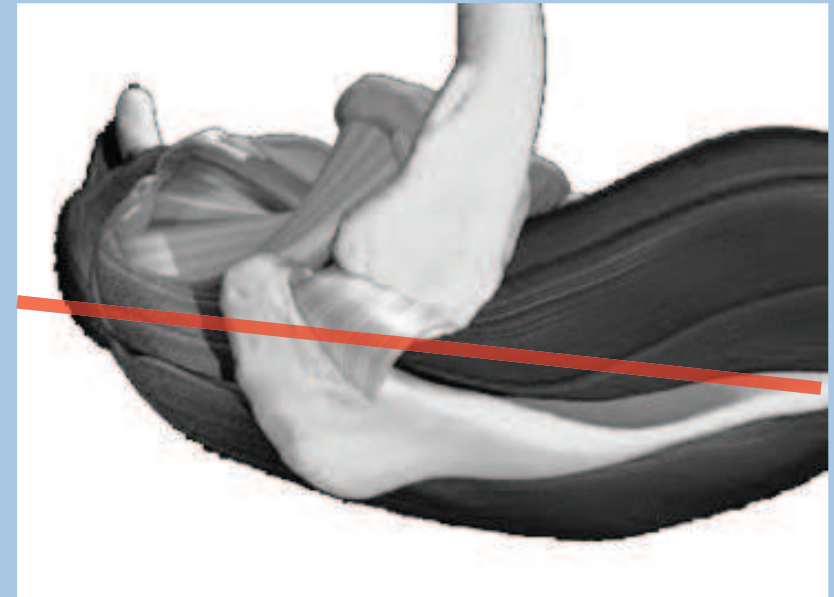
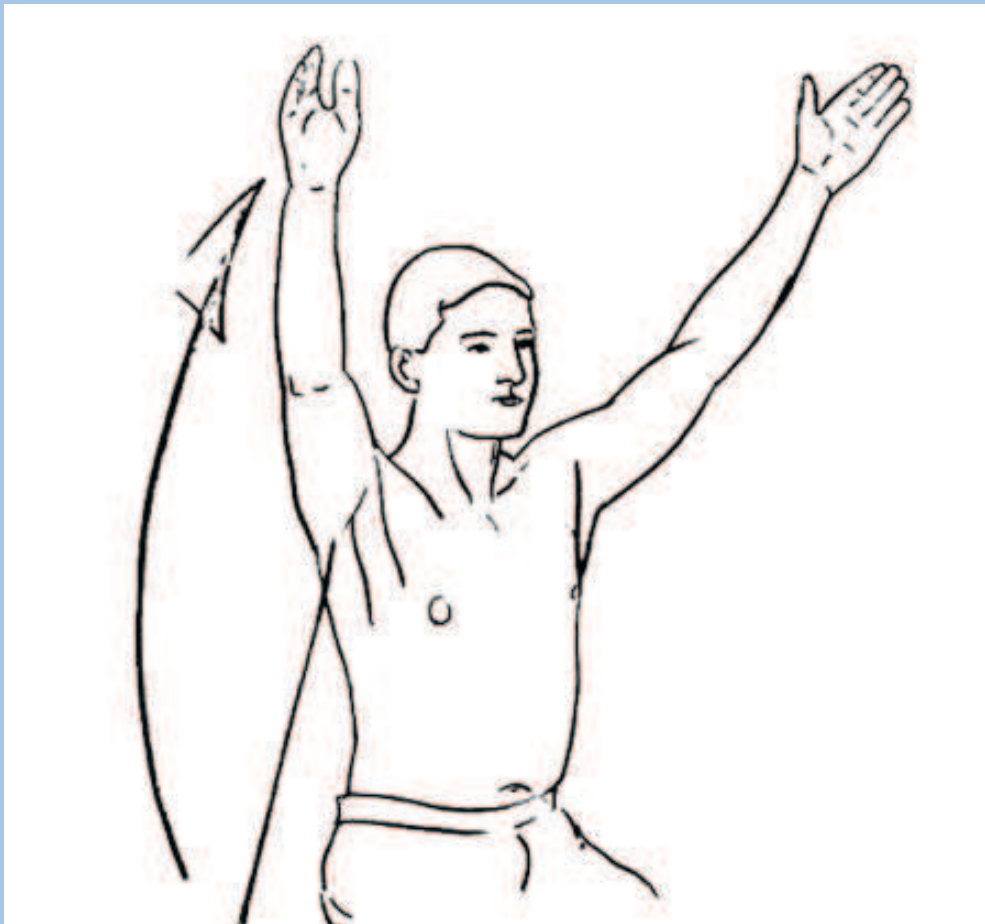Documentation in Degrees



ELEVATION

FUNCTION

Documentation in Degrees



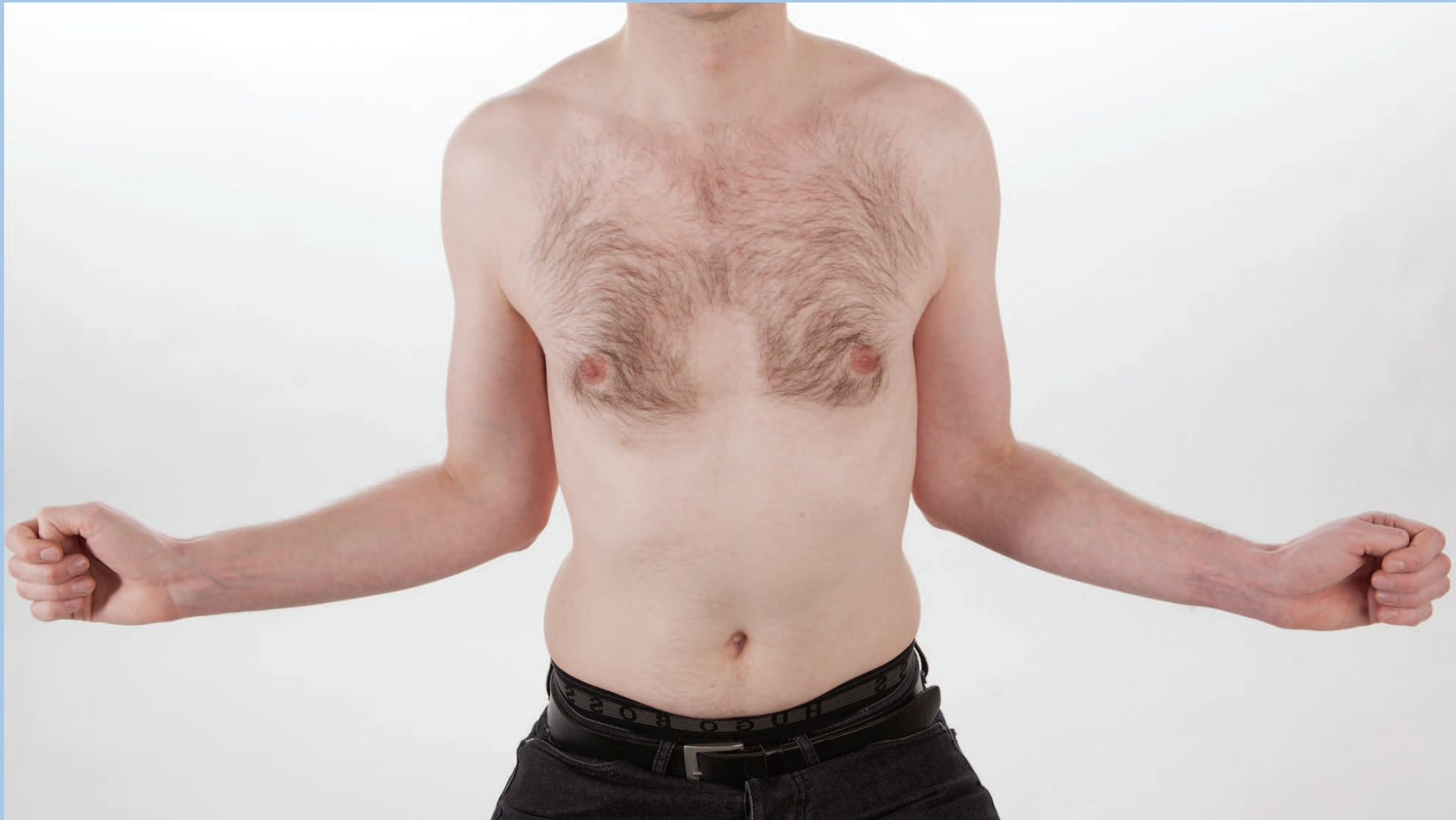EXTERNAL ROTATION (ER)

FUNCTION

u^b

UNIVERSITÄT
BERN

Documentation in Degrees

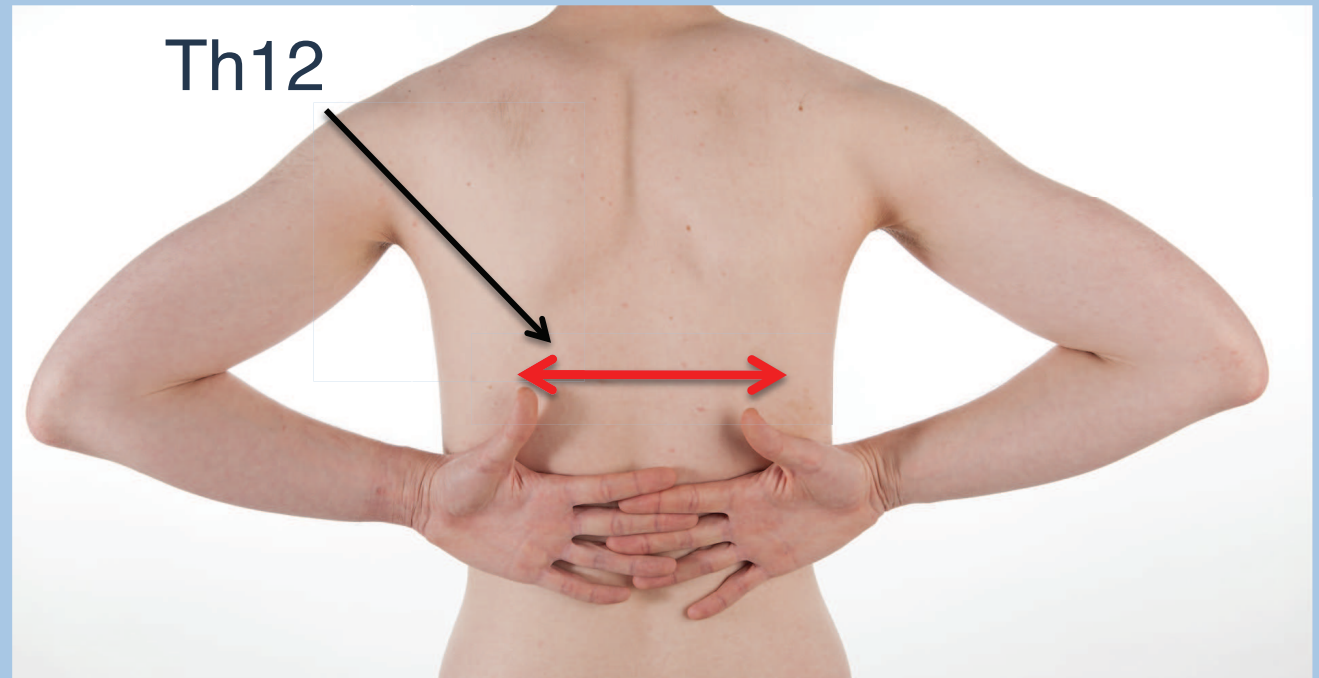


INTERNAL ROTATION (IR)

FUNCTION

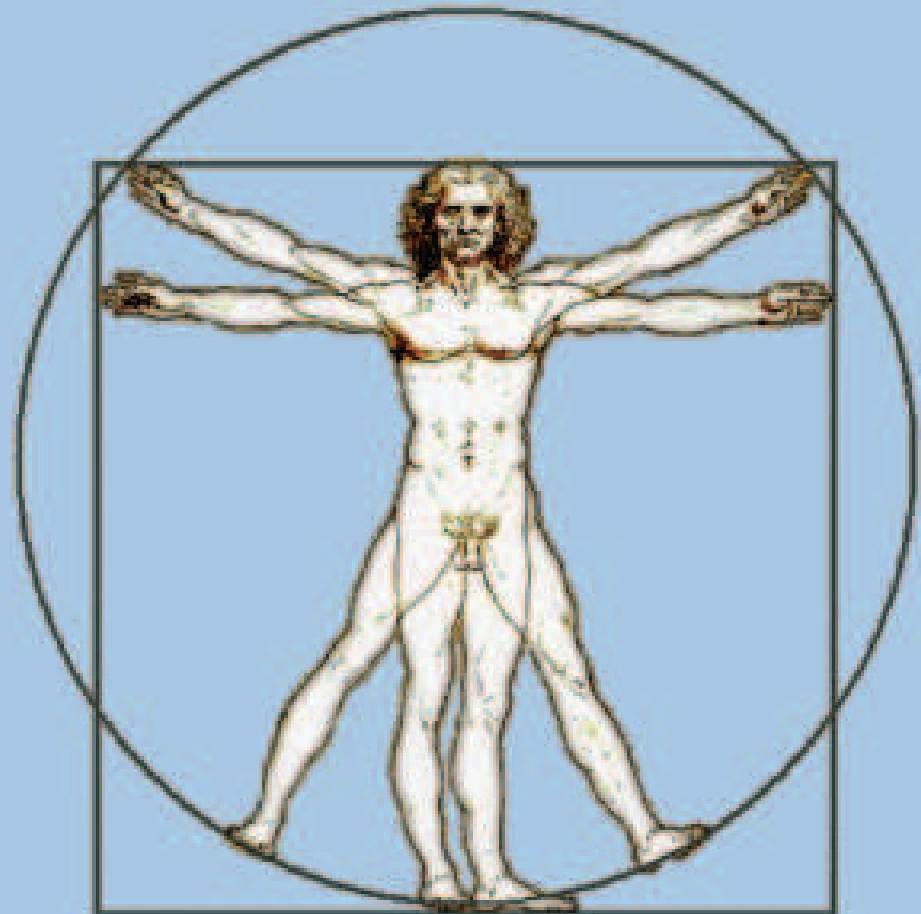
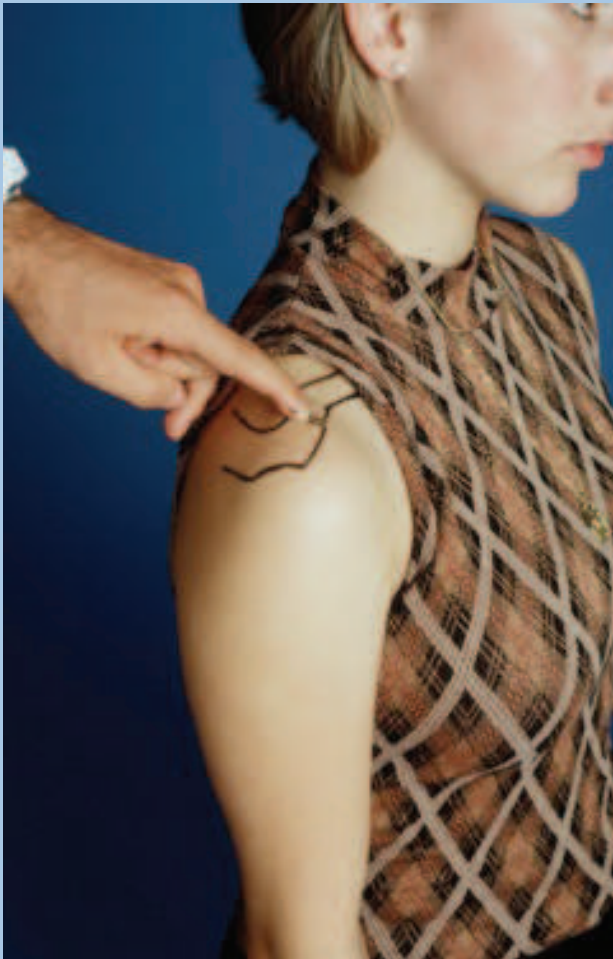Documentation in levels

- gluteal
- Sacrum
- LW3
- Th10/Th12



AC-ARTRHOPATHY

Painful arc $> 120^\circ$ abduction

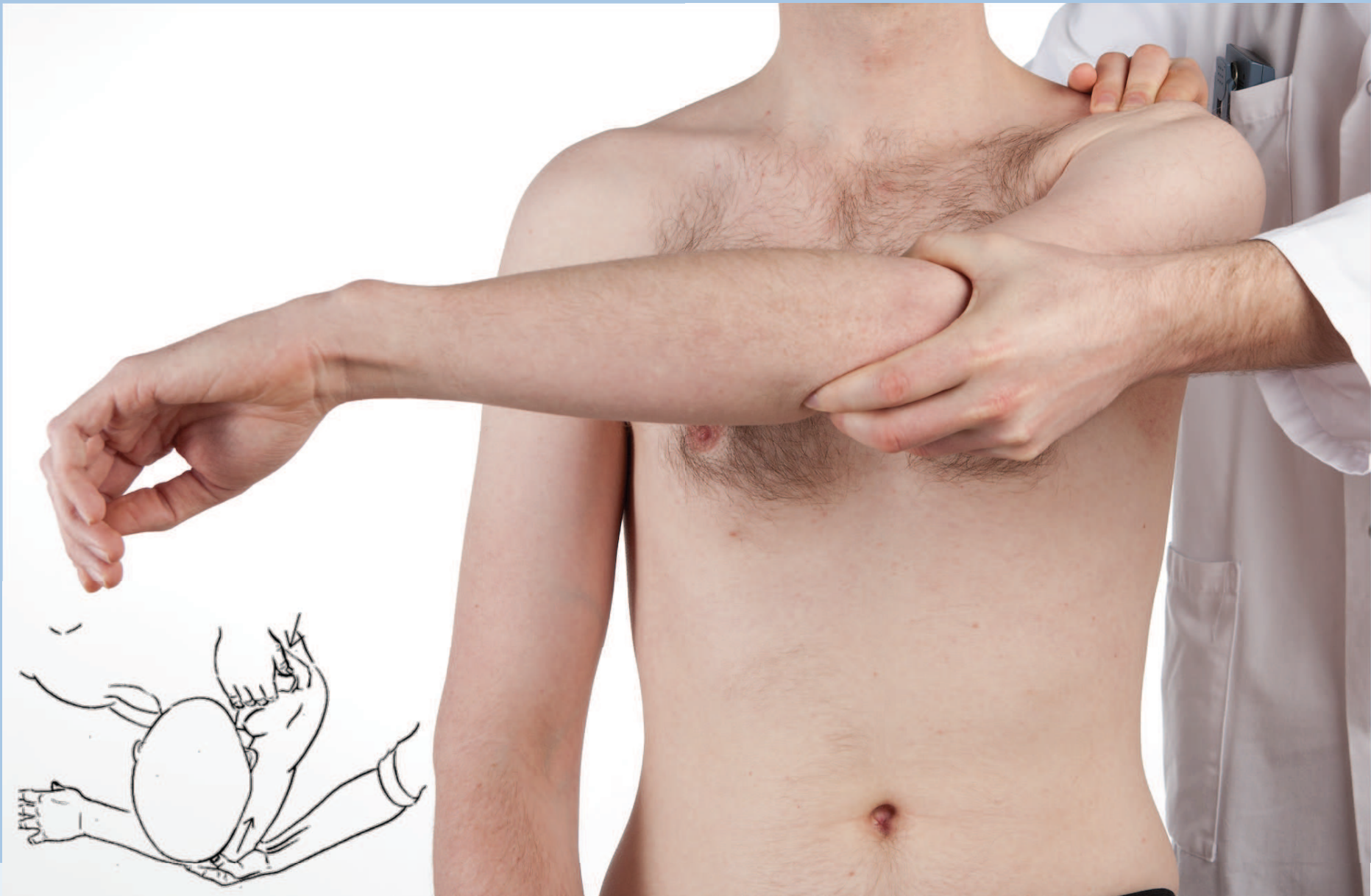

„BODY CROSS“ TEST

FUNCTION

u^b

UNIVERSITÄT
BERN

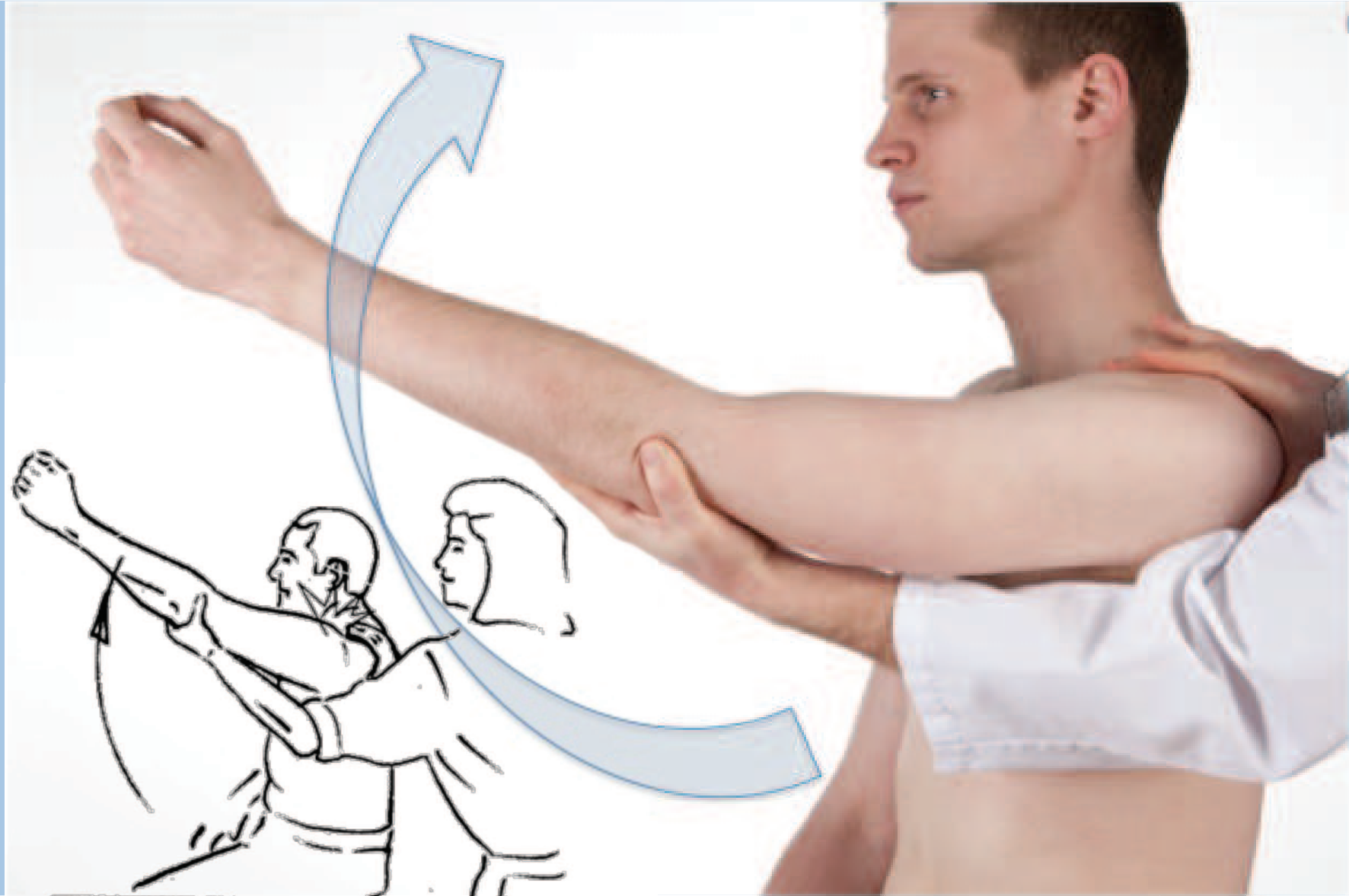


NEER IMPINGEMENT SIGN

FUNCTION

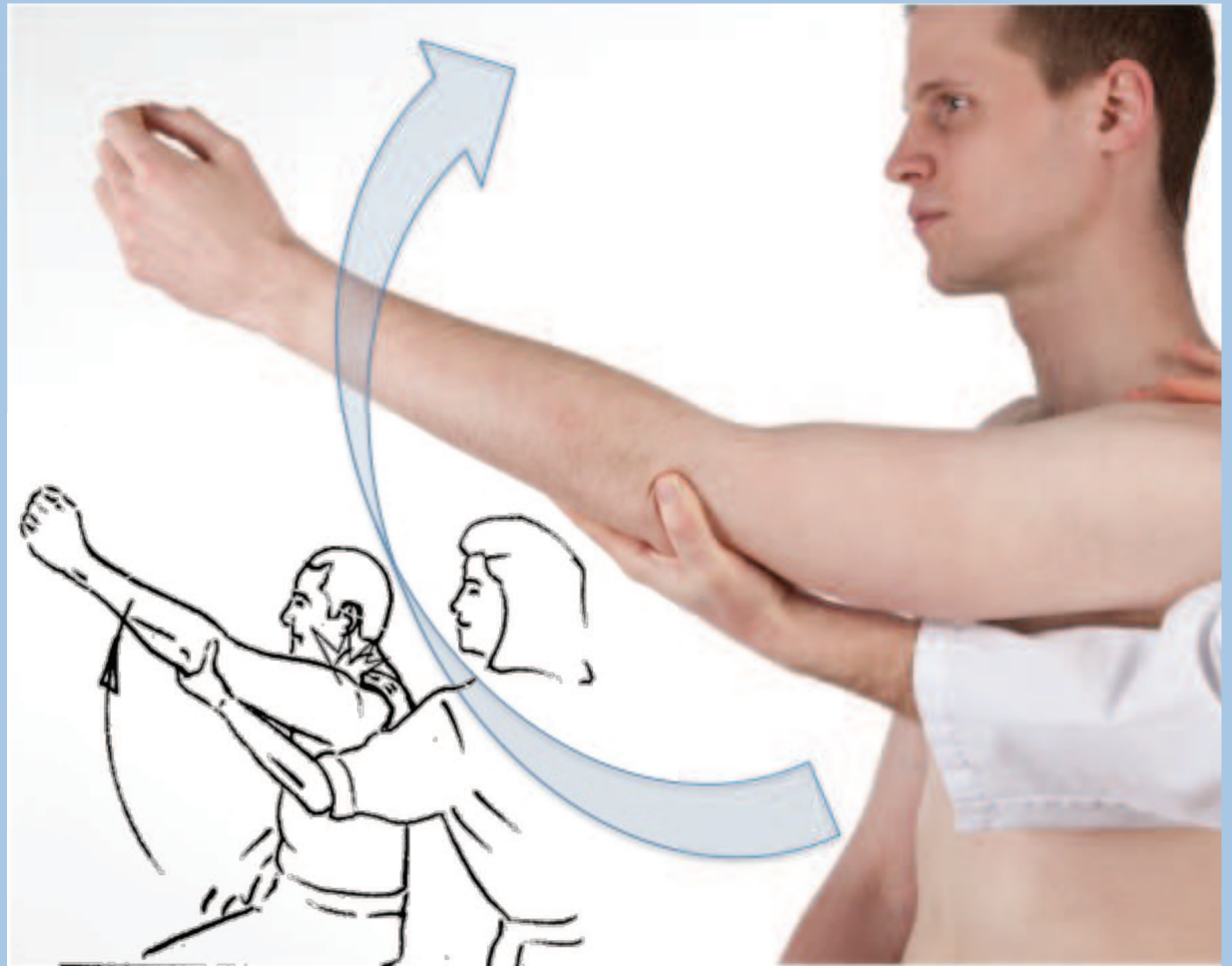
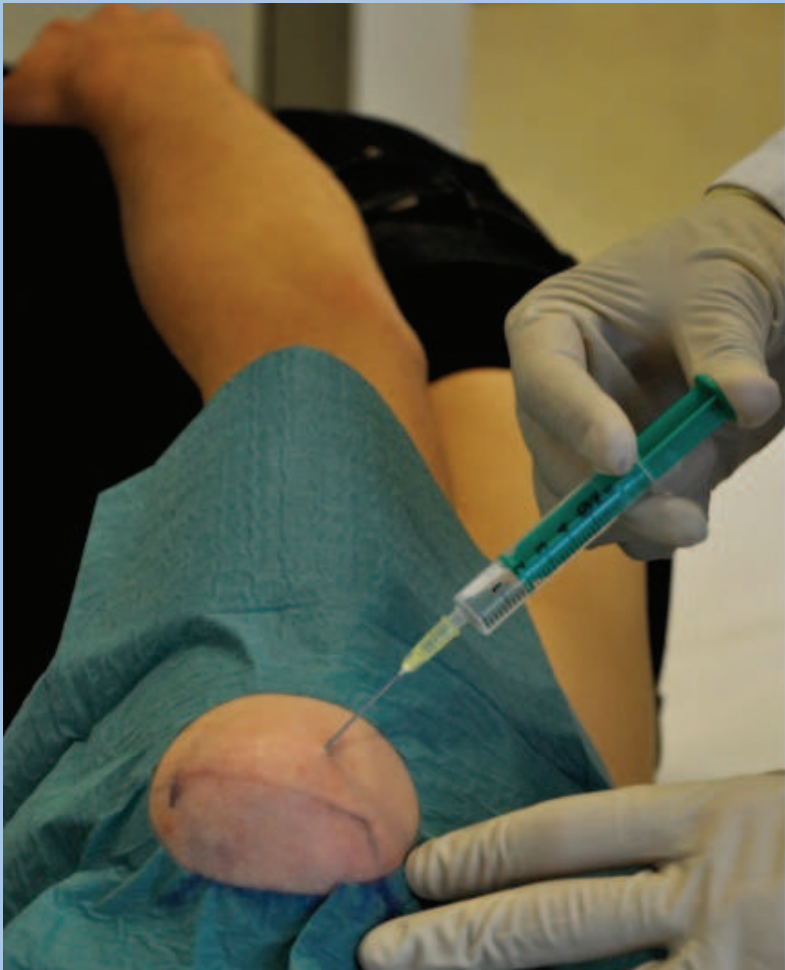u^b

UNIVERSITÄT
BERN



NEER IMPINGEMENT TEST

FUNCTION



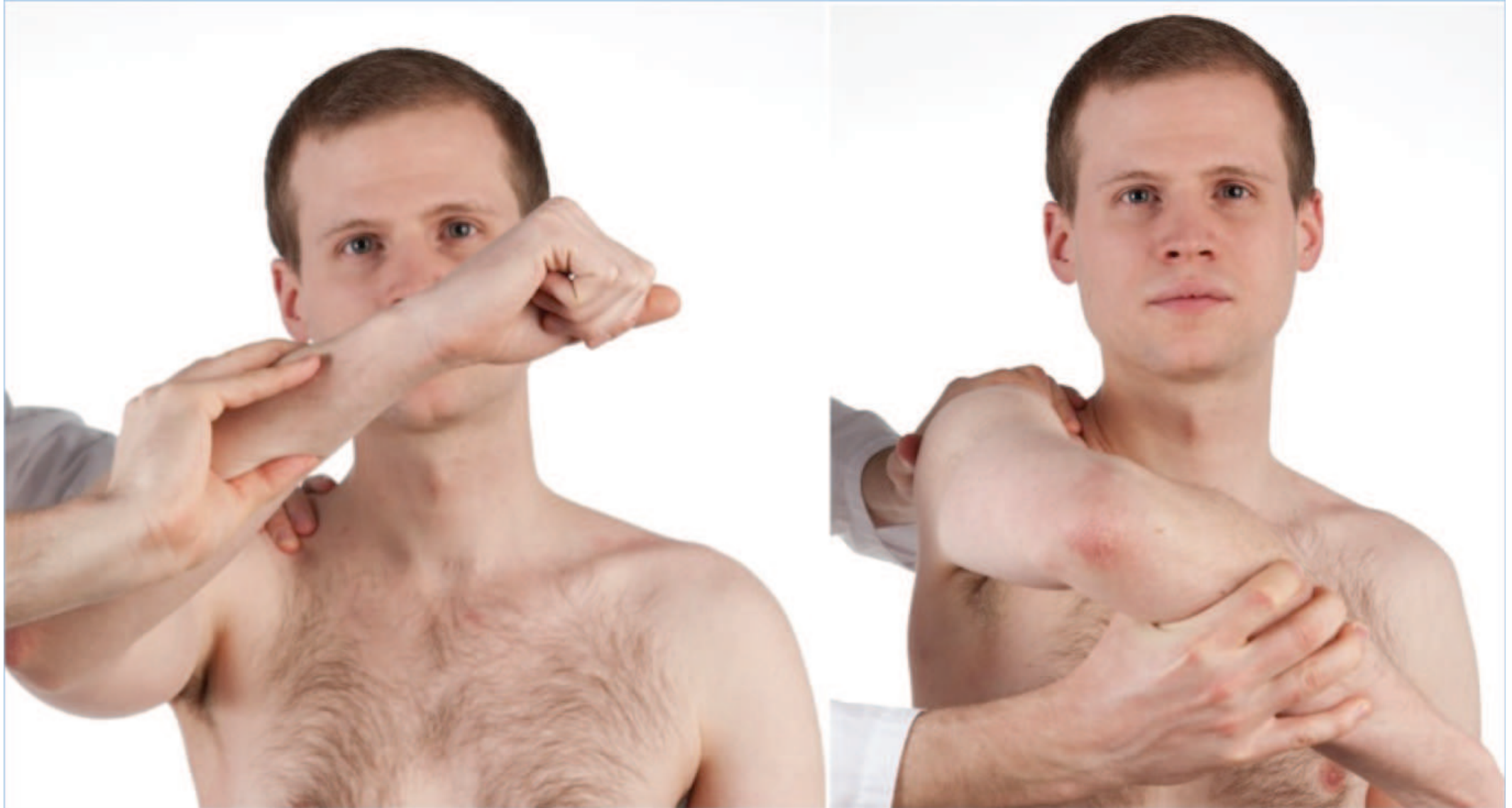
(5- 10 ml 1% Lidocaine in subacromial space)

HAWKINS / KENNEDY

FUNCTION

u^b

UNIVERSITÄT
BERN

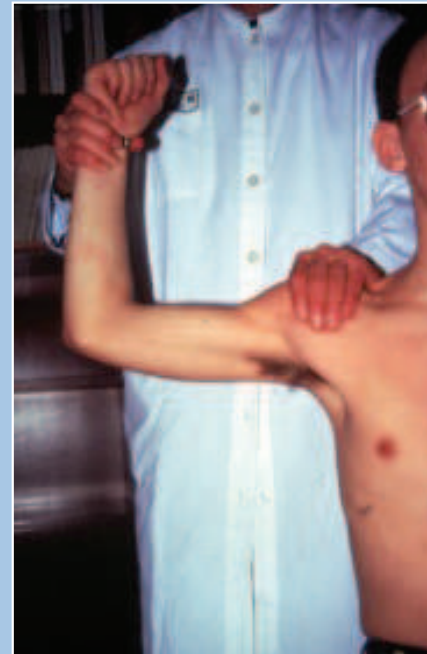

WALCH TEST

FUNCTION

Postero-superiorer Impingement

→ Impingement of SSP between head and glenoid



ABER

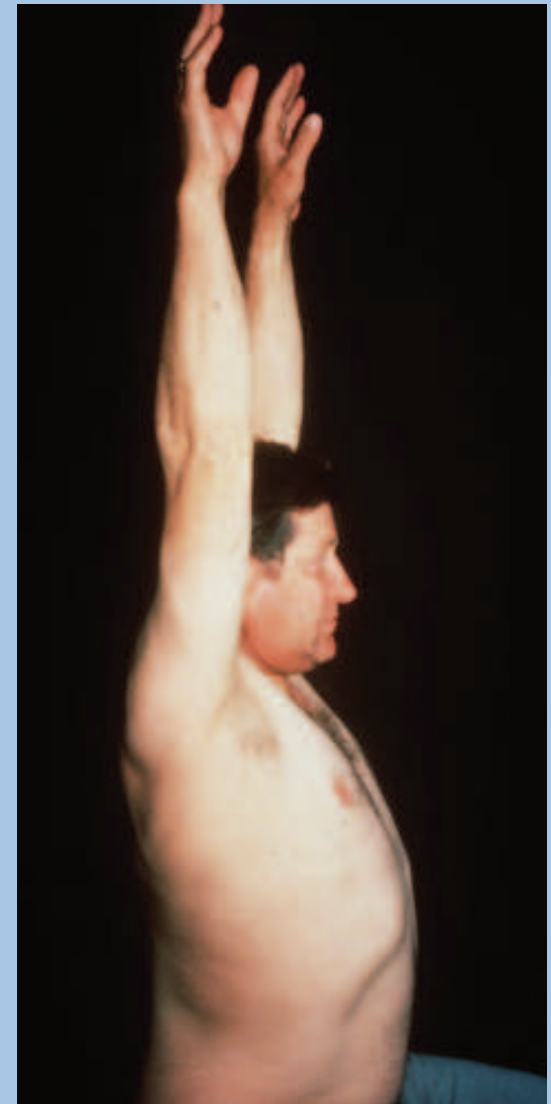


Dorsal pain
No apprehension

SUPRASPINATUS

FUNCTION

- Pain at night and during overhead activities
- Normal motion in 95% with full thickness tear
- Weakness in elevation (Scapular plain)



JOBE TEST

FUNCTION

- **CAVE: only weakness!**

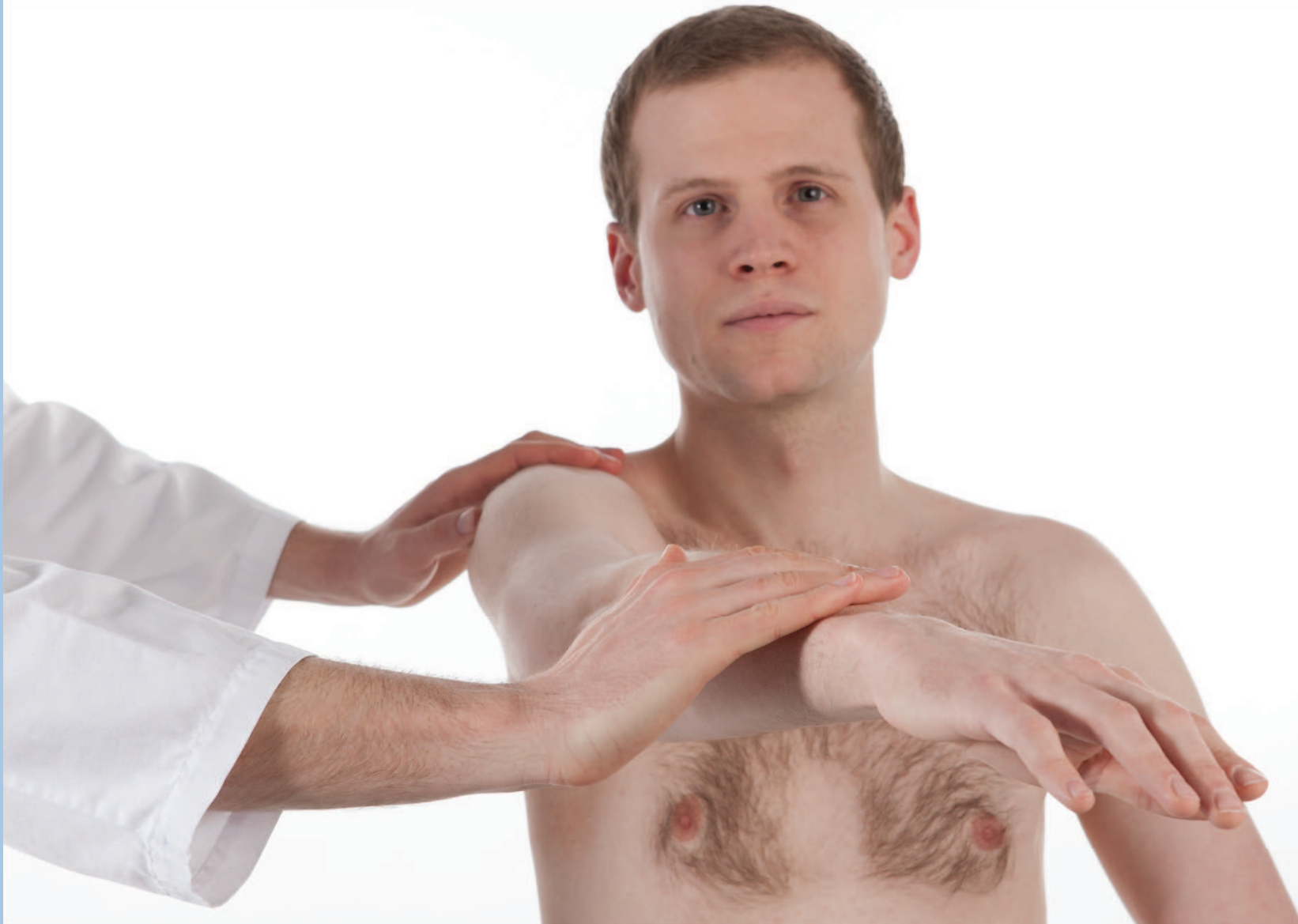

WHIPPLE TEST

FUNCTION

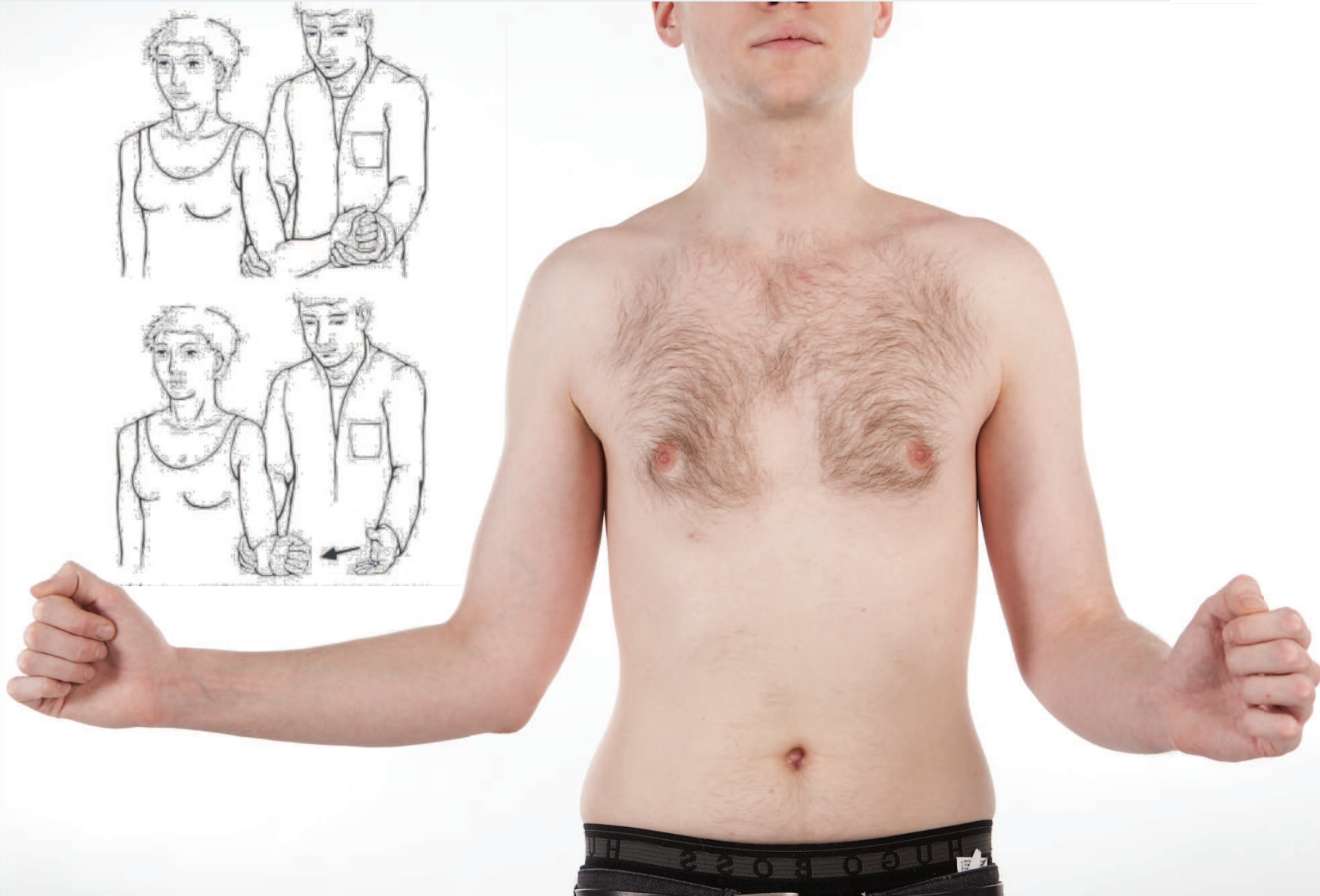
u^b

UNIVERSITÄT
BERN



ER-LAG $< 15^\circ$

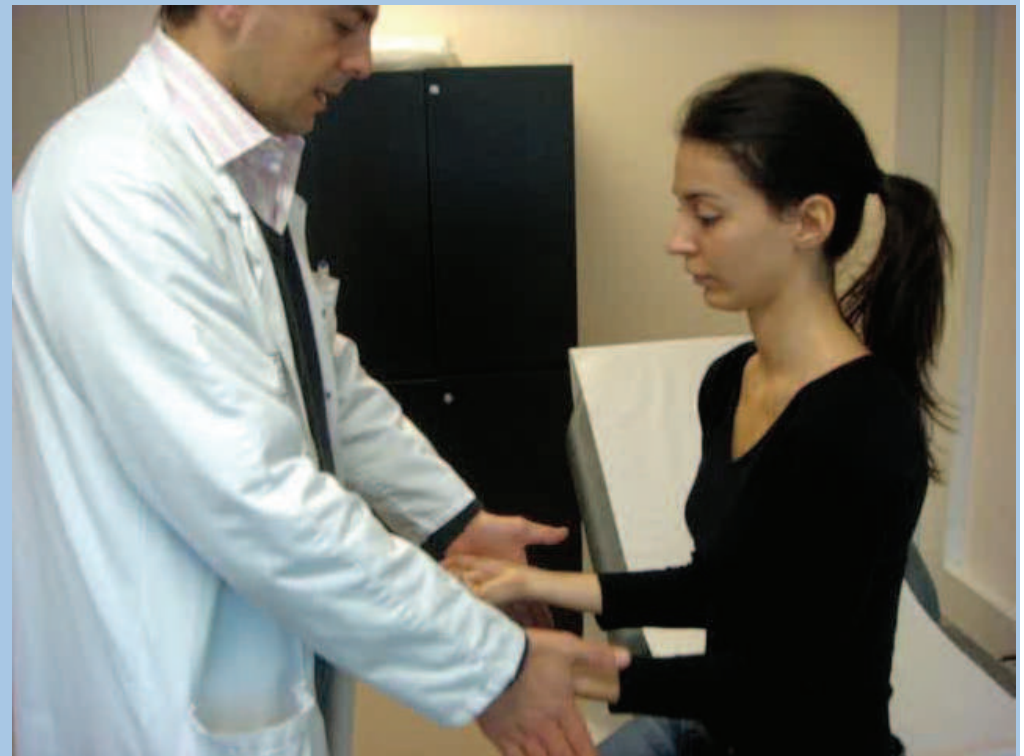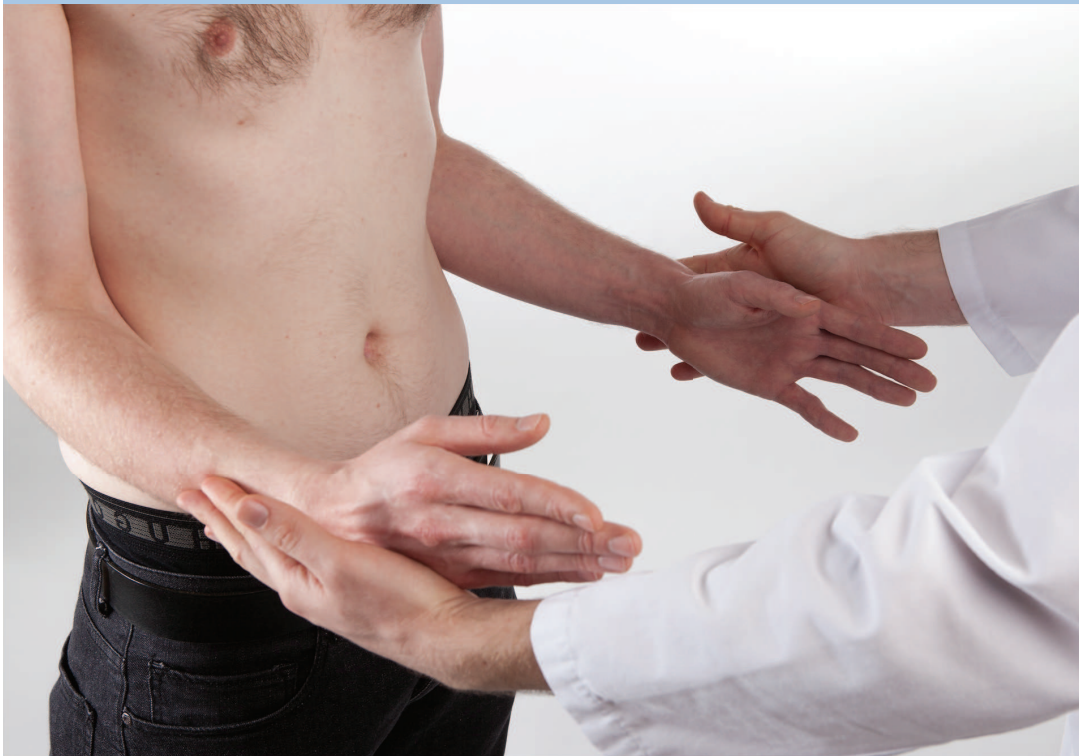FUNCTION



ER FORCE

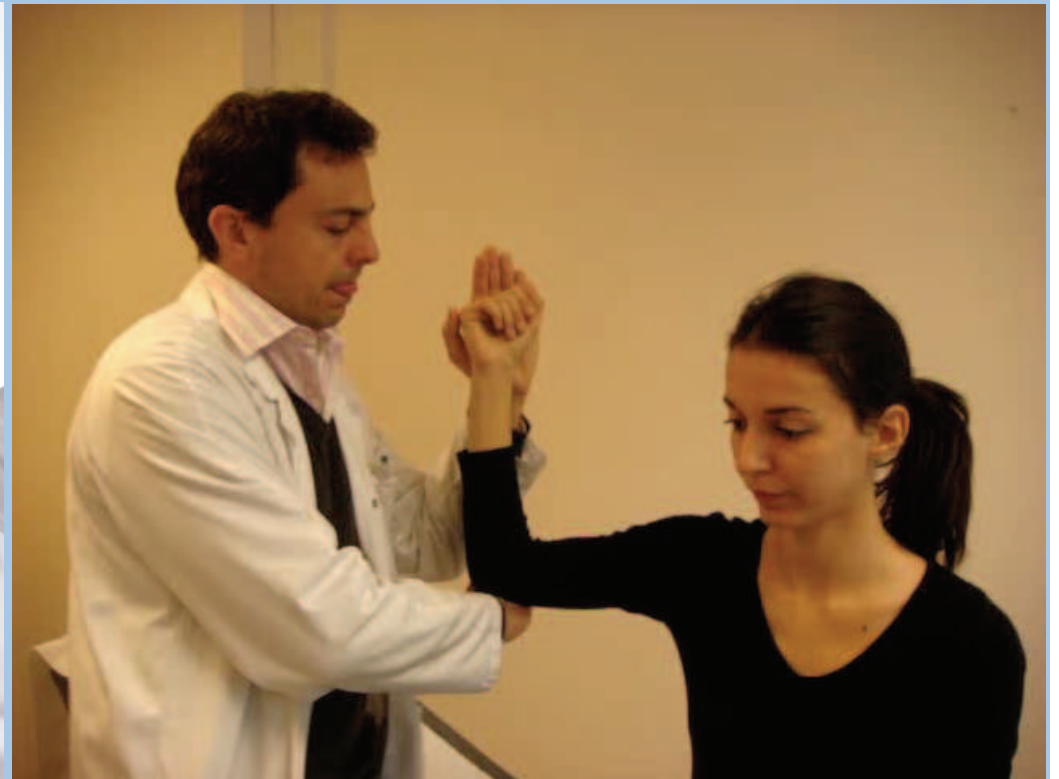FUNCTION

Arm in adduction



PATTE TEST

FUNCTION

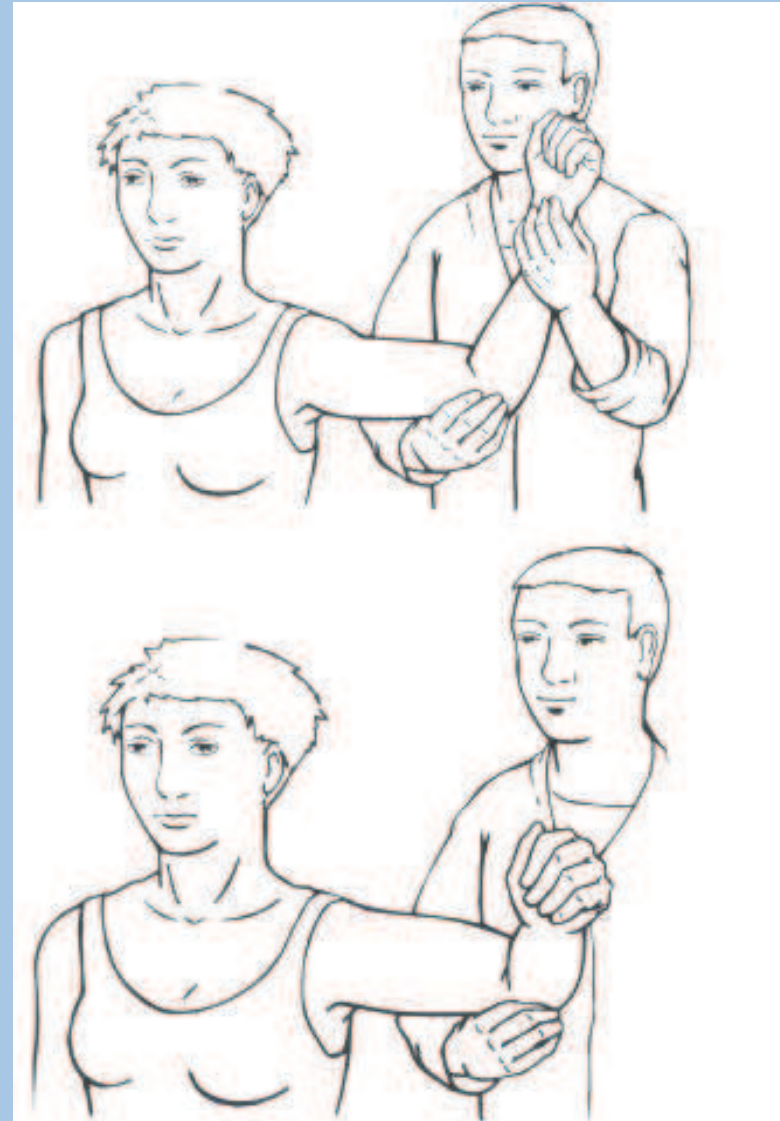
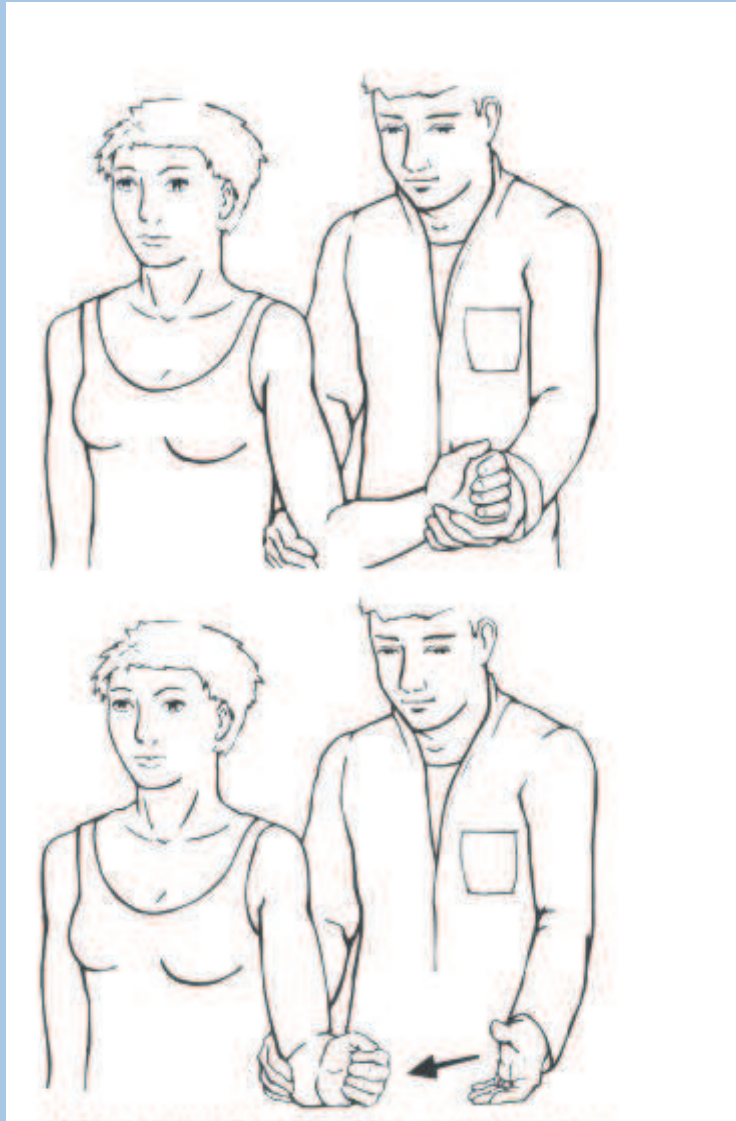

ER-LAG $> 15^\circ$

FUNCTION

u^b

UNIVERSITÄT
BERN

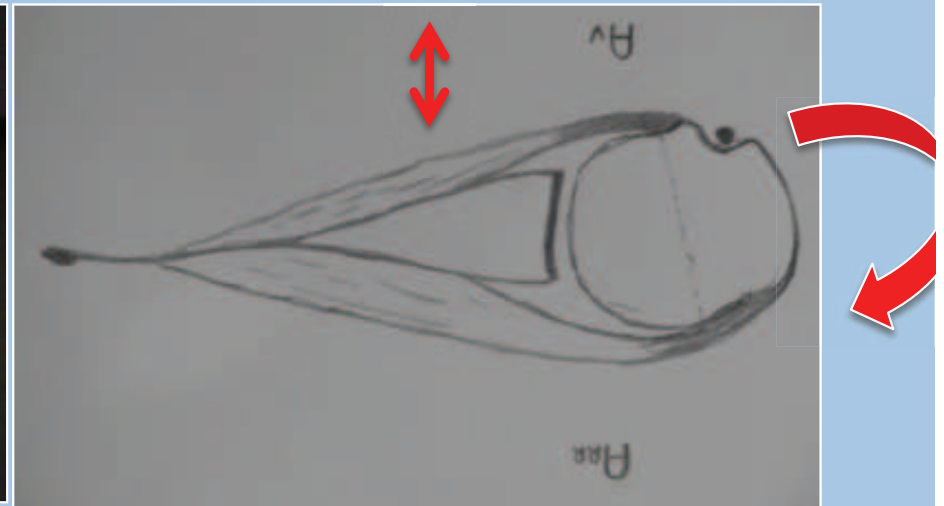
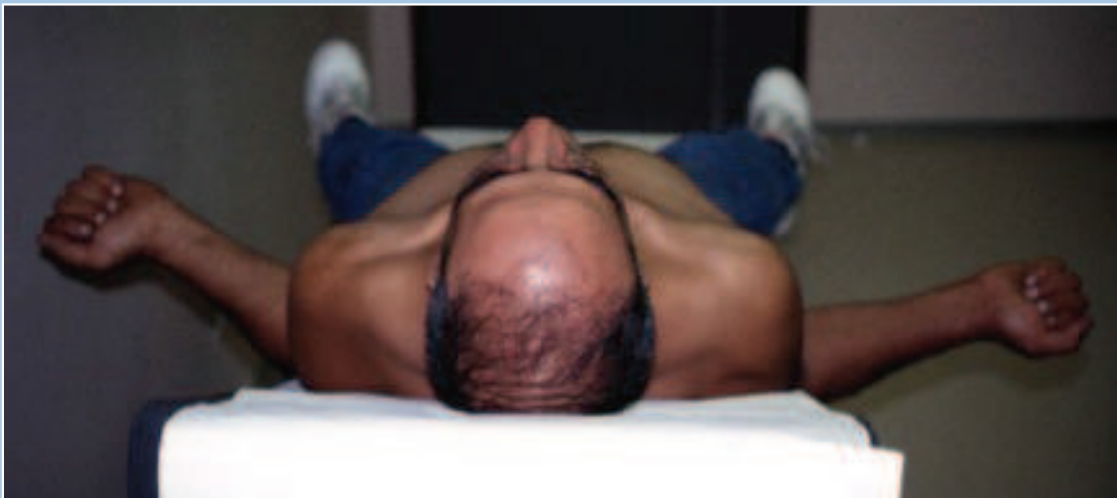

SUBSCAPULARIS

FUNCTION

Increased passive ER

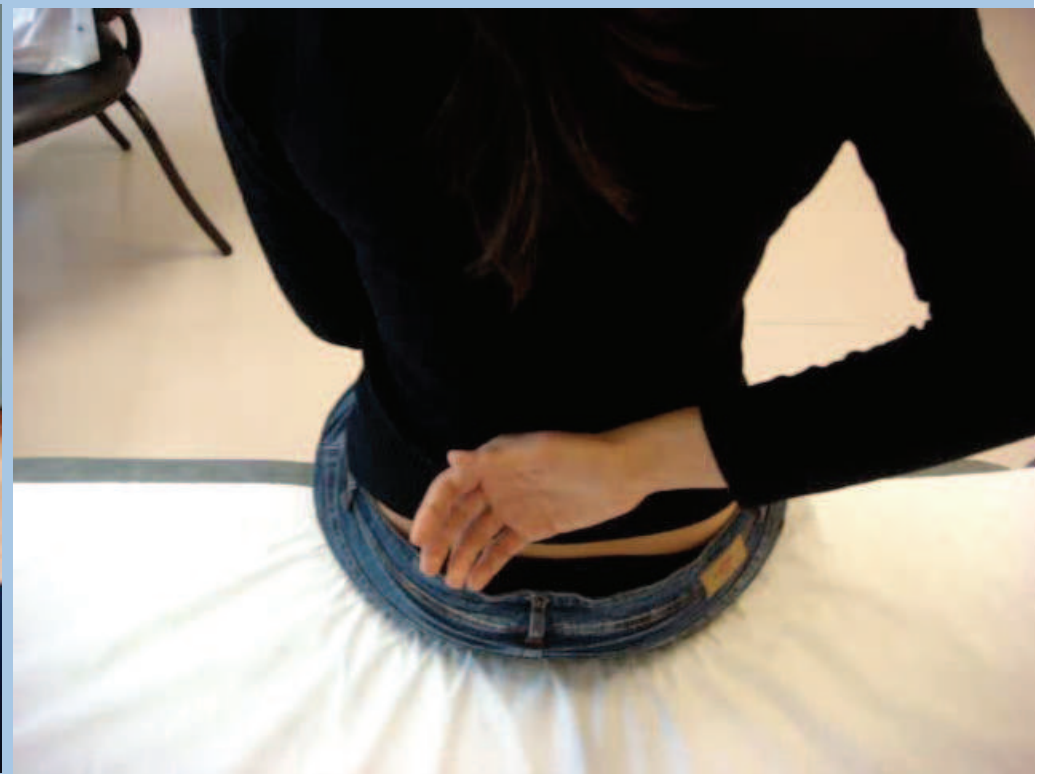
→ Loss of anterior brake



LOSS OF ACTIVE IR

FUNCTION

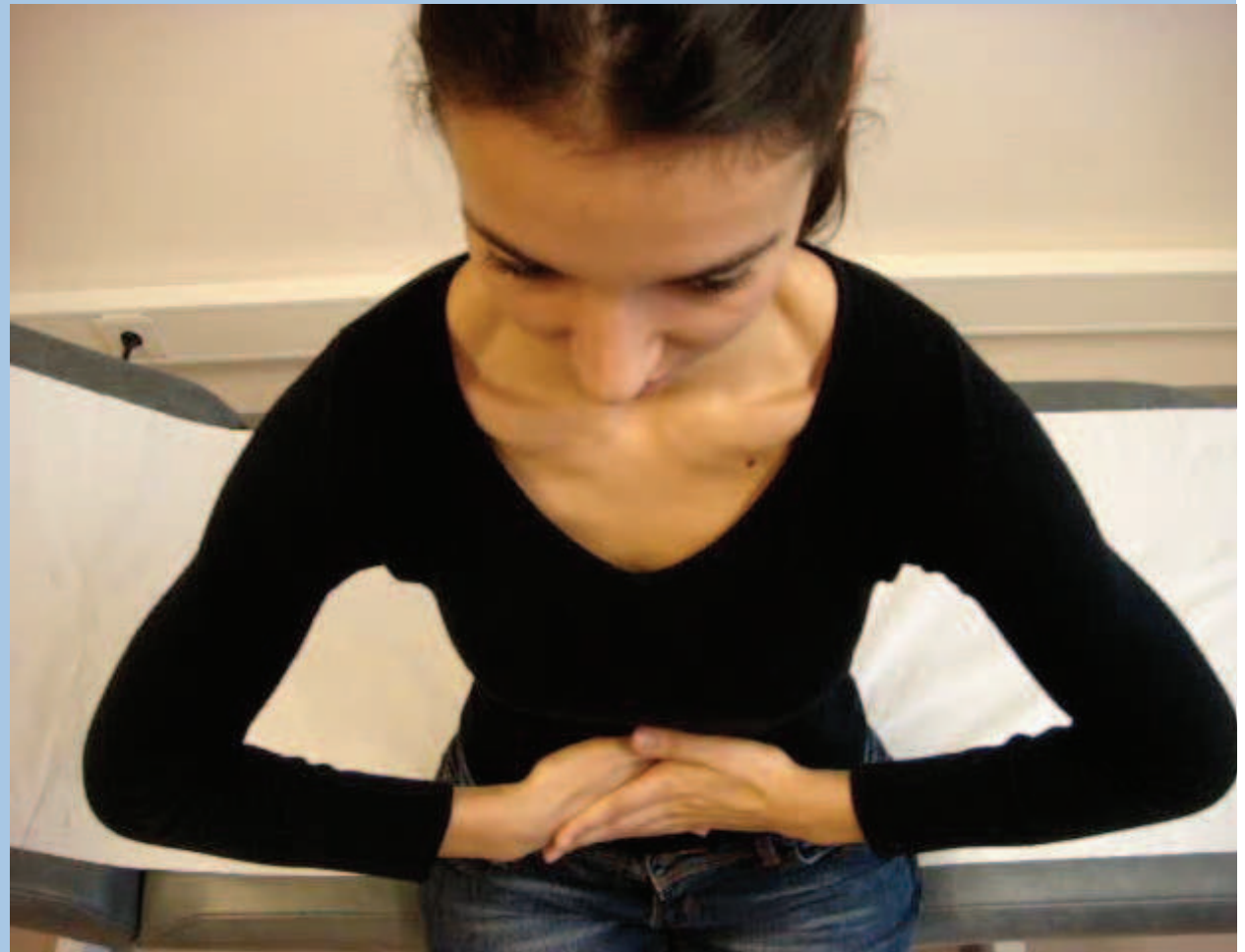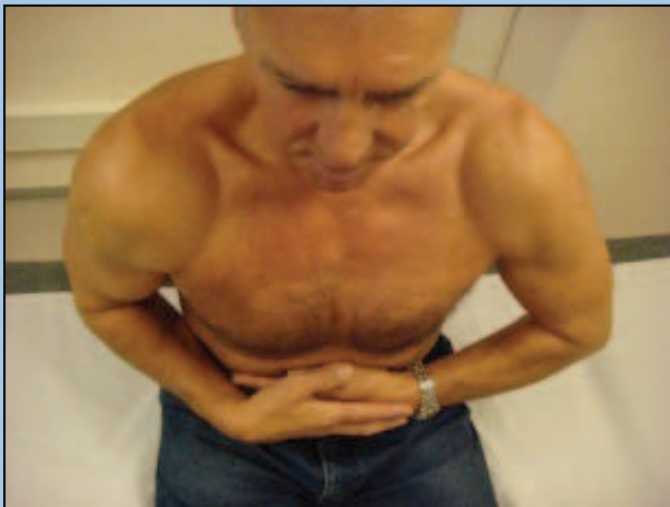Lift off Test and IR-Lag



LOSS OF PASSIVE IR

FUNCTION

Belly press Test

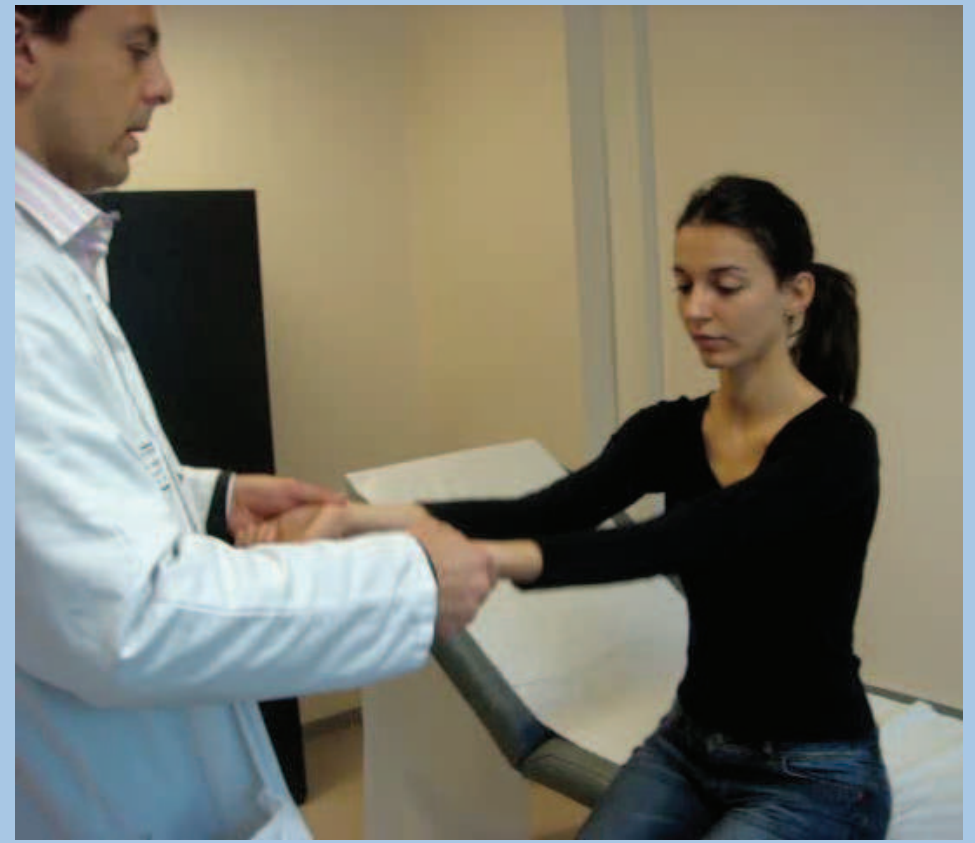

PALM UP TEST

FUNCTION

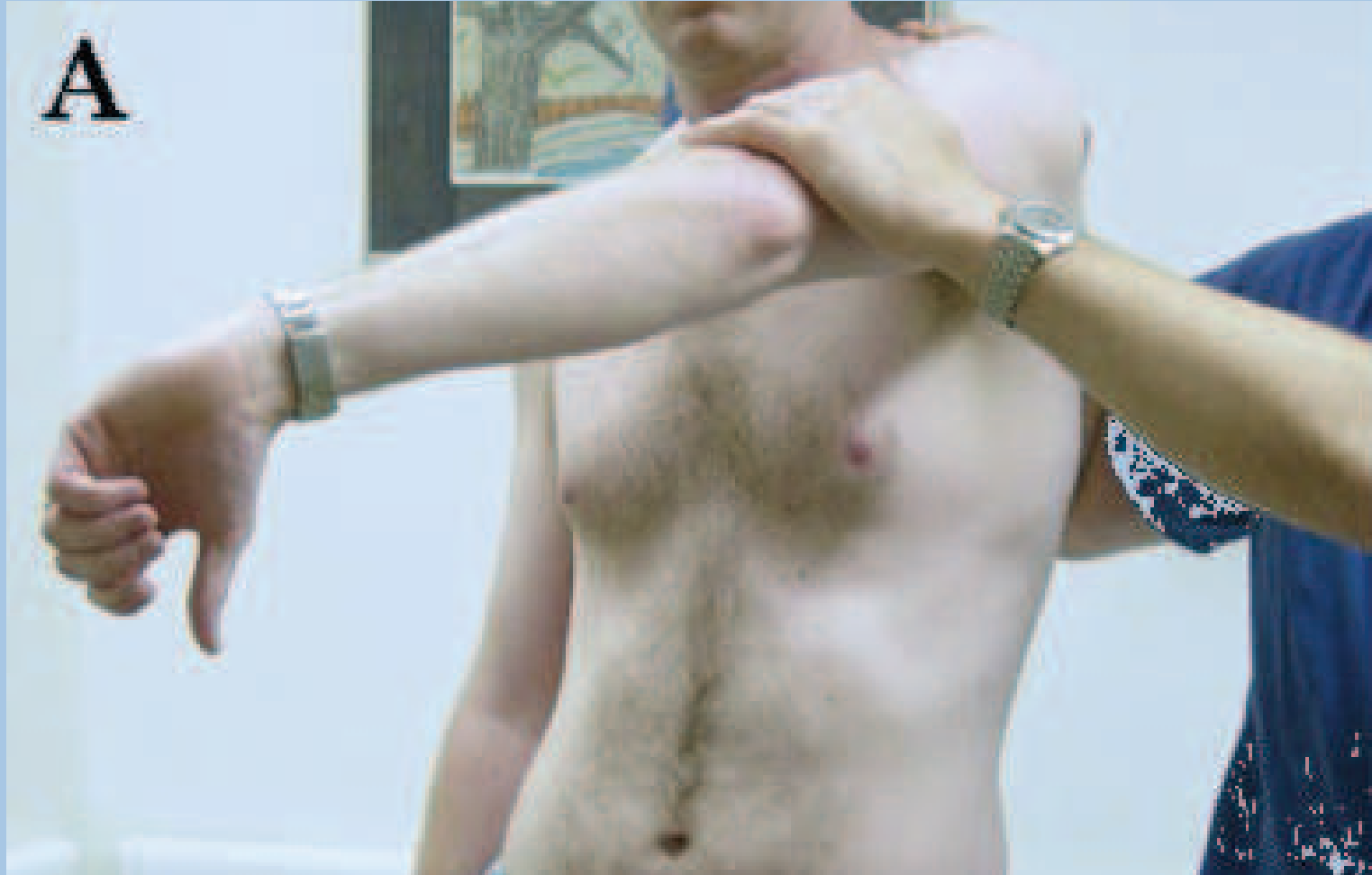u^b

UNIVERSITÄT
BERN



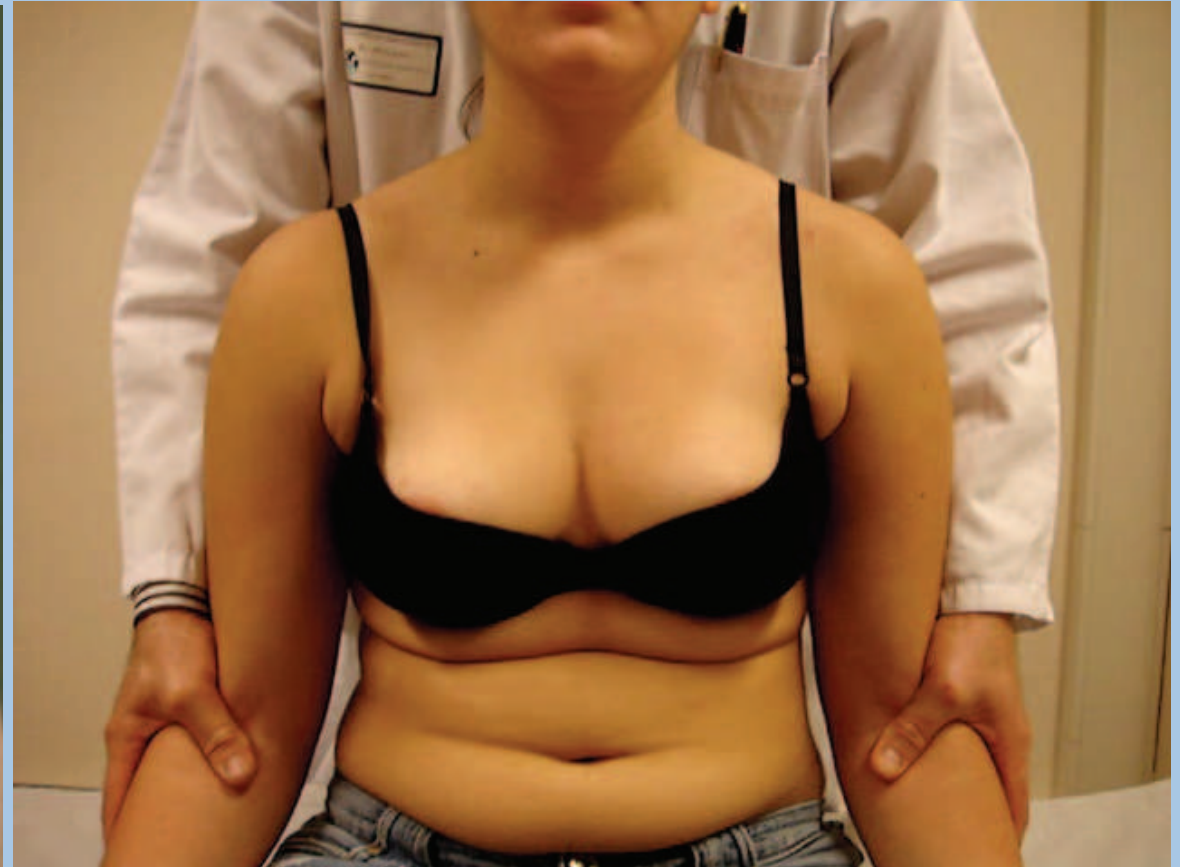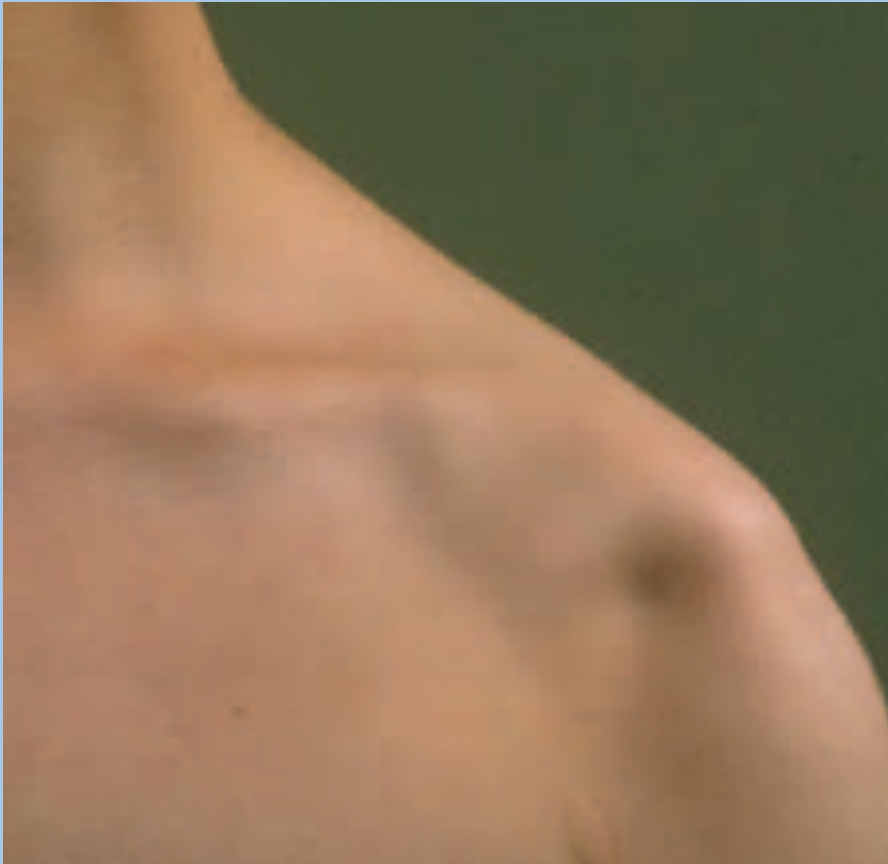O'BRIEN TEST

FUNCTION




SULCUS SIGN

FUNCTION



GENERALIZED HYPERLAXITY

FUNCTION



ANTERIOR HYPERLAXIZITY

FUNCTION

u^b

UNIVERSITÄT
BERN



passive ER $\geq 85^\circ$

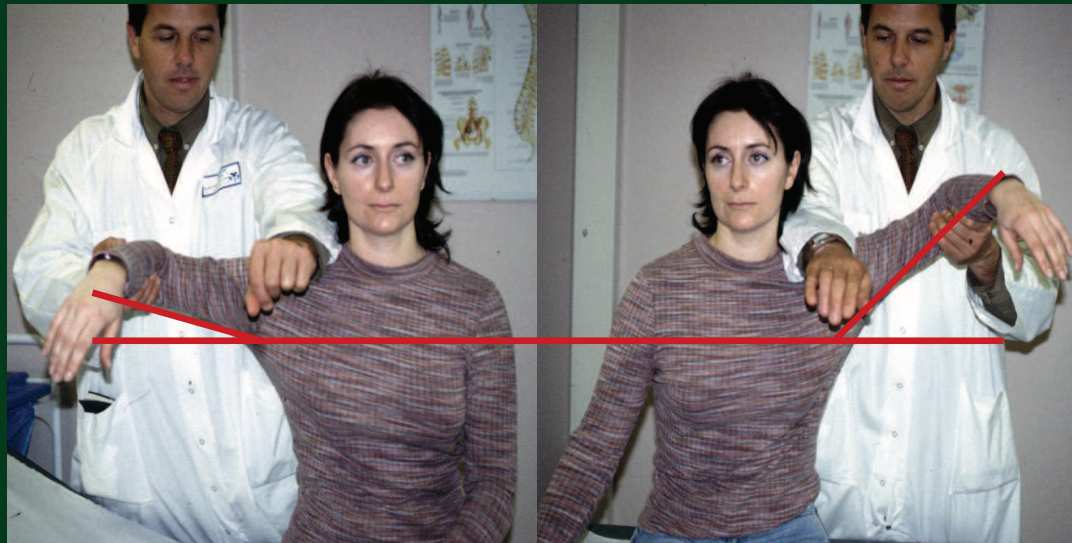HYPERABDUCTION

FUNCTION

Side to side difference more than 20°
„Lachman“ of the shoulder

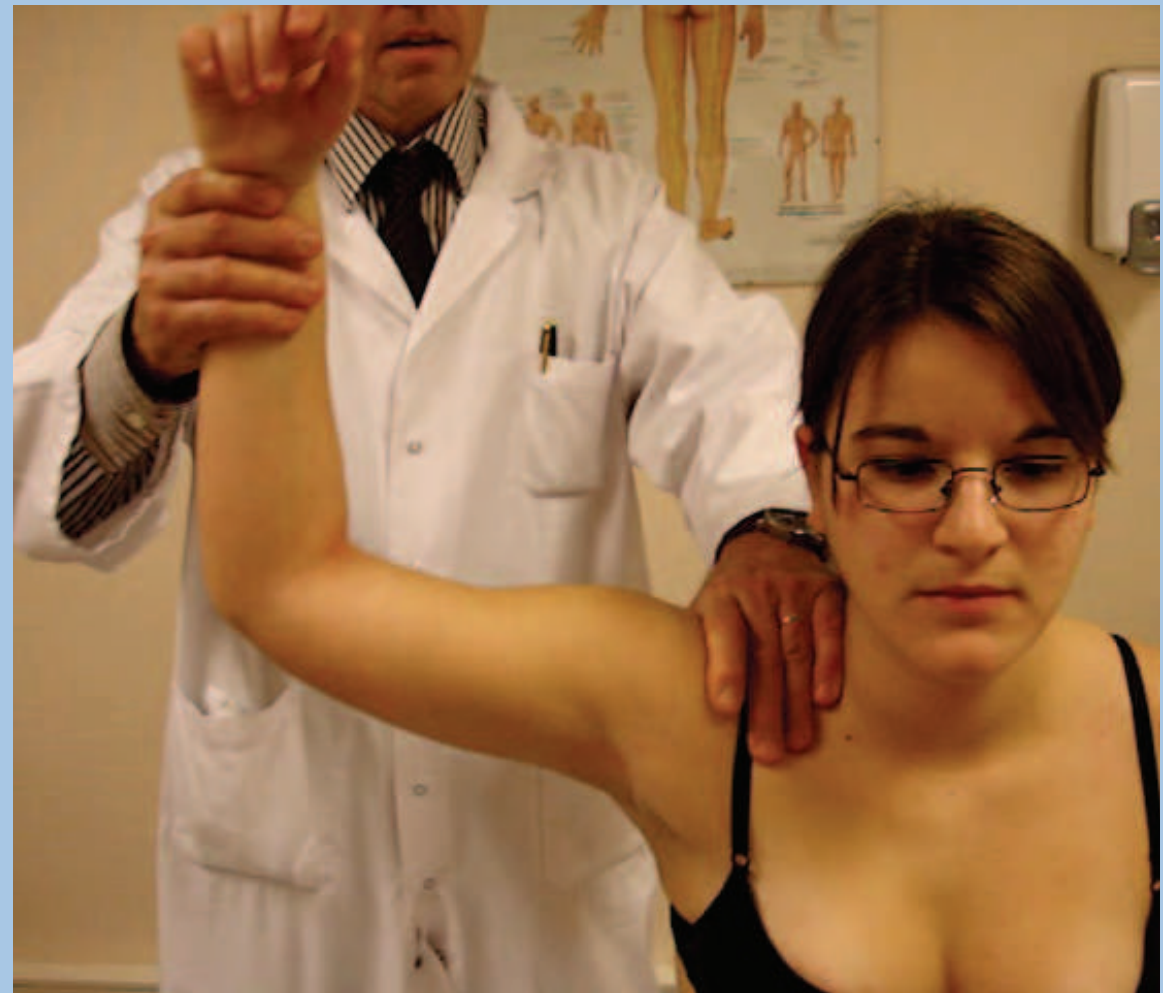Inferior Shoulder hyperlaxity :

**Side to side difference in hyperabduction >20°
(Gagey Test)**



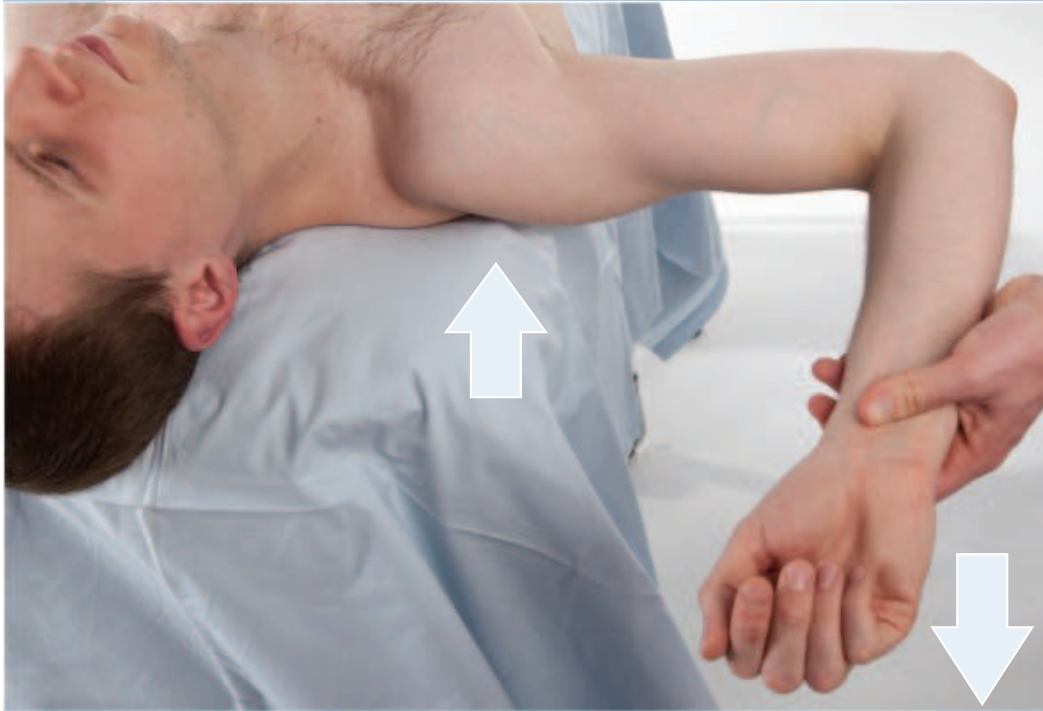ANTERIOR APPREHENSION

FUNCTION

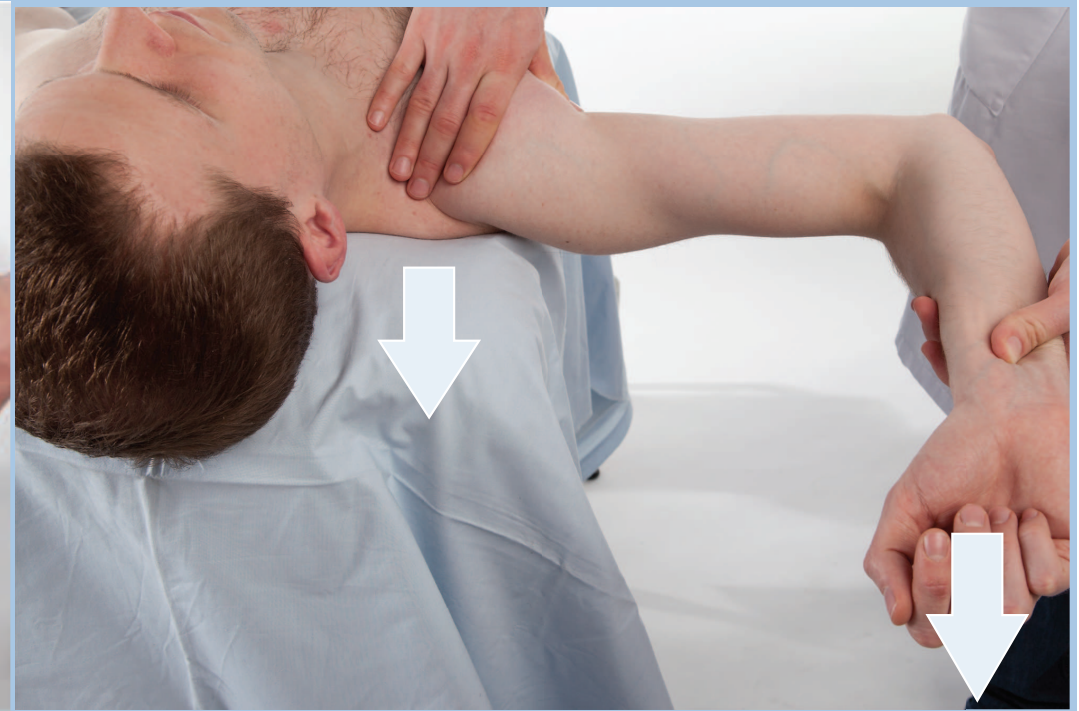

RELOCATION

FUNCTION



**Apprehension and/or
pain**



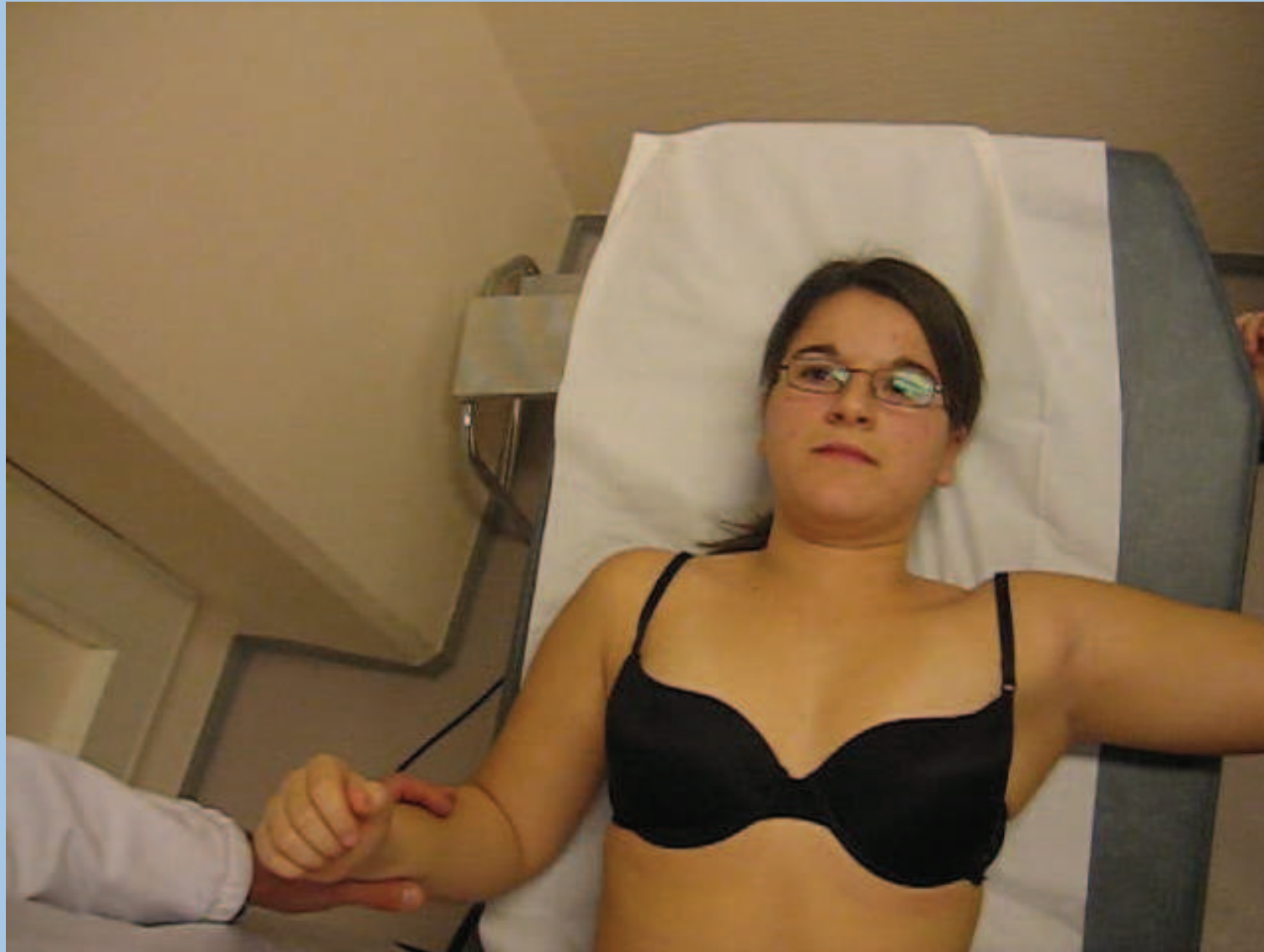**Apprehension and/or
pain ↘**

RELOCATION

FUNCTION

u^b

UNIVERSITÄT
BERN

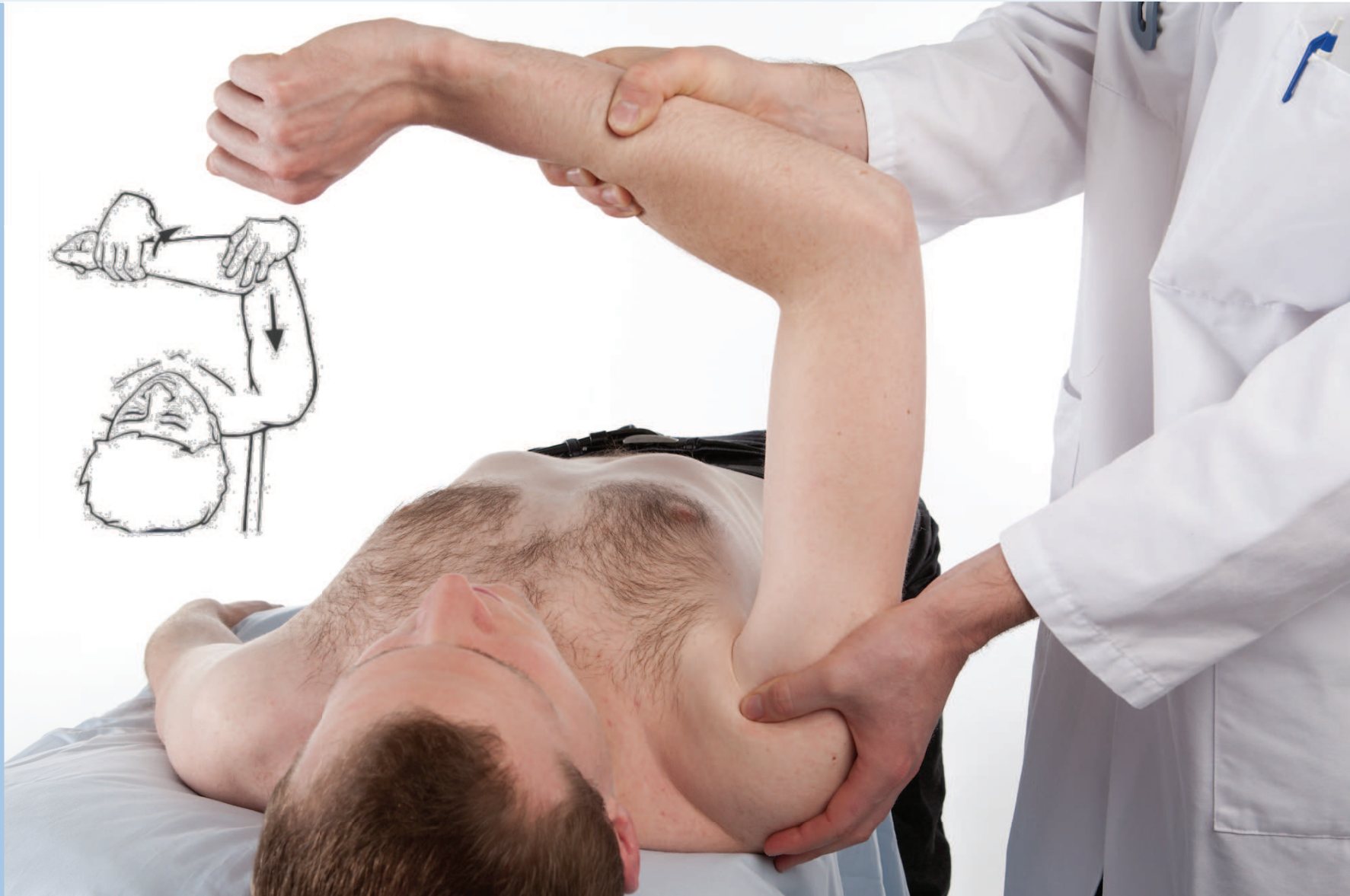

POSTERIOR APPREHENSION

FUNCTION

u^b

UNIVERSITÄT
BERN



TAKE HOME MESSAGES

- **Detailed clinical analysis**
- **Diagnosis after clinical assessment**
- **Complementary investigations (Rx, MRI, CT) to confirm suspected diagnosis**

TAKE HOME MESSAGES

- always bilateral exam (look for asymmetries)
- Active versus passive limitation of ROM
- LAG = Difference between active and passive ROM
- Normal ROM possible with torn SSP
- Laxity \neq Instability

THANK YOU !



Remy Flückiger, MD
Shoulder, Elbow & Orthopedic Sports Medicine
Department of Orthopedic Surgery and Traumatology
University of Berne, Switzerland
remy.flueckiger@insel.ch

RULE OF „3“

