

Elbow

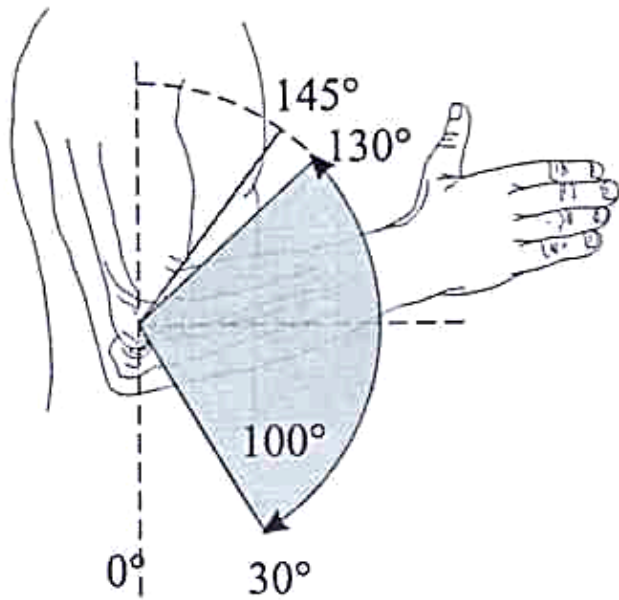
clinical examination

Dr Stéphane Kämpfen

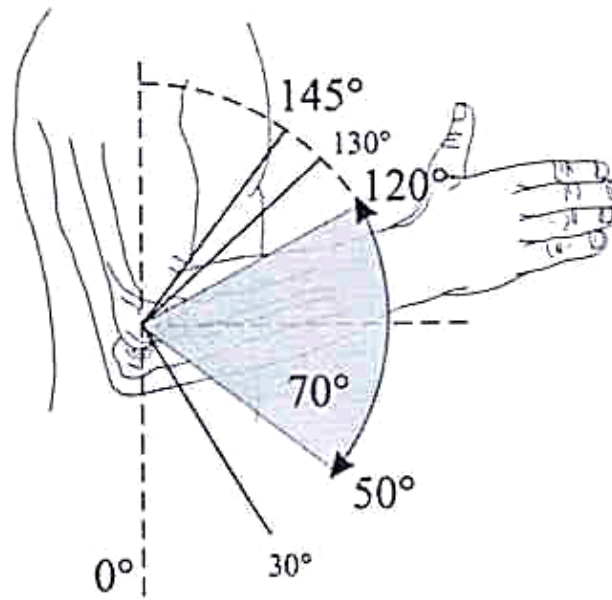


Centre de chirurgie et de thérapie de la main
Genève

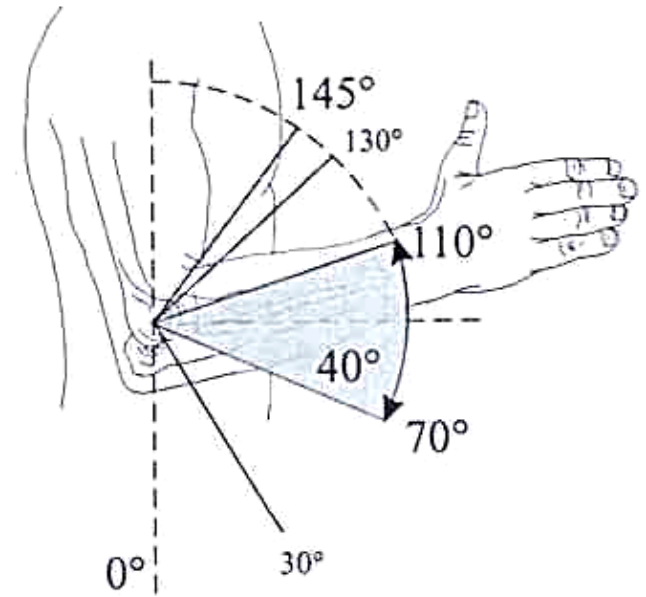
Function



Functional Arc

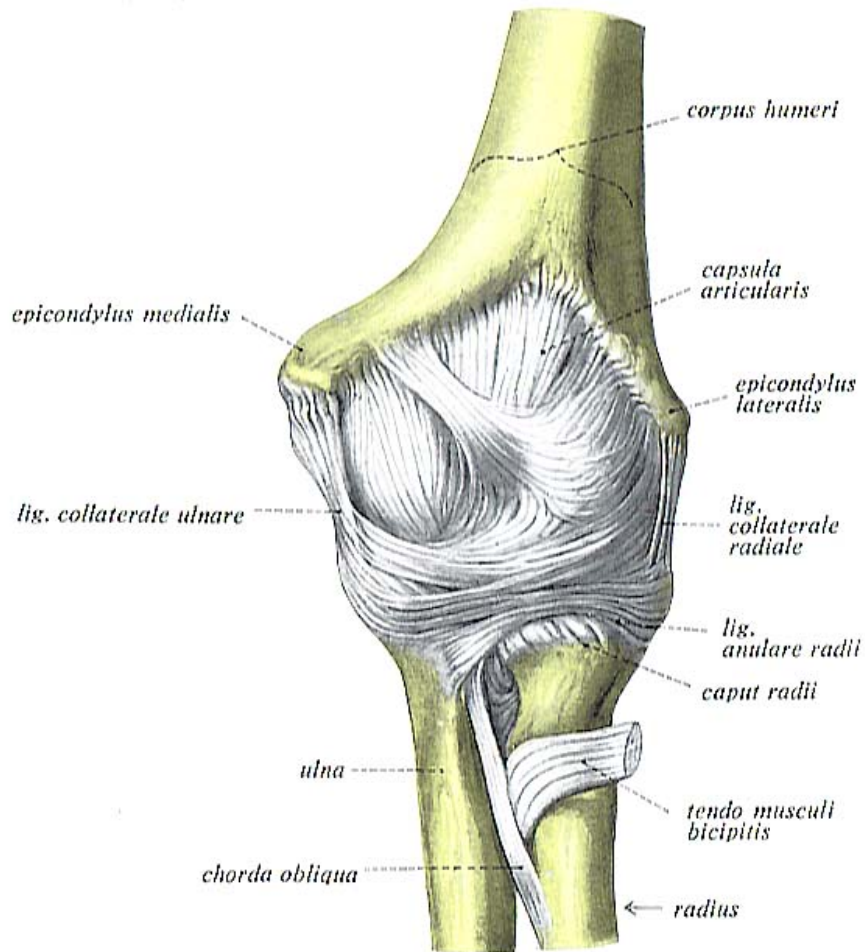


Optimum 70° Arc

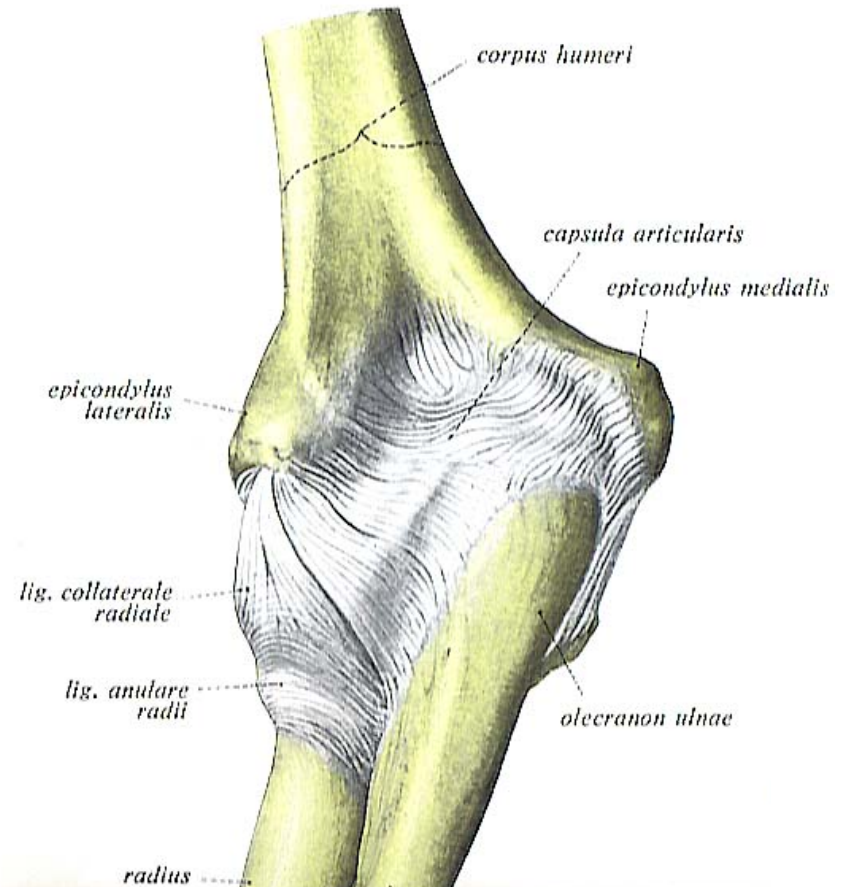


Optimum 40° Arc

Anatomy



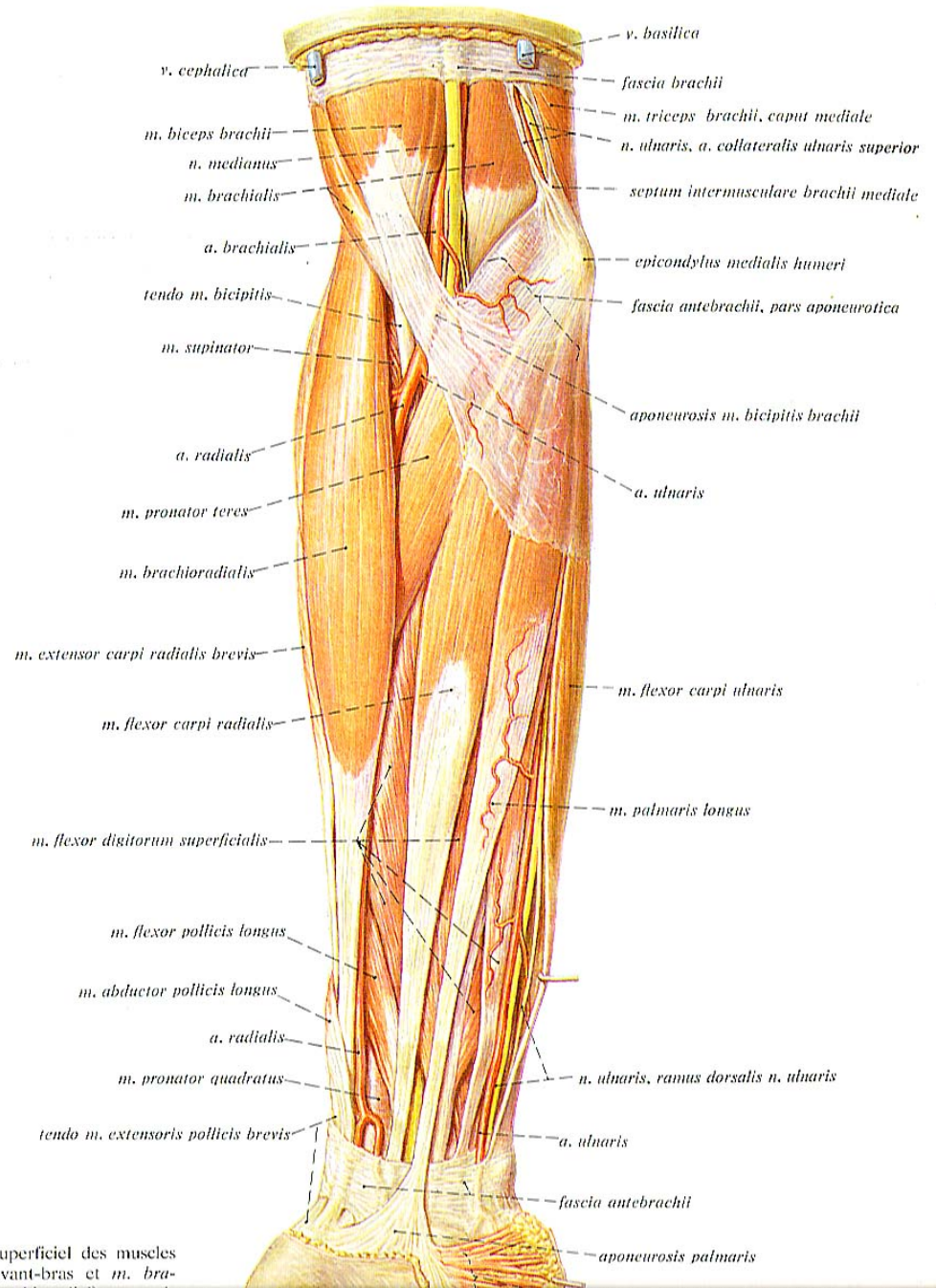
Anterior



Posterior

Anatomy

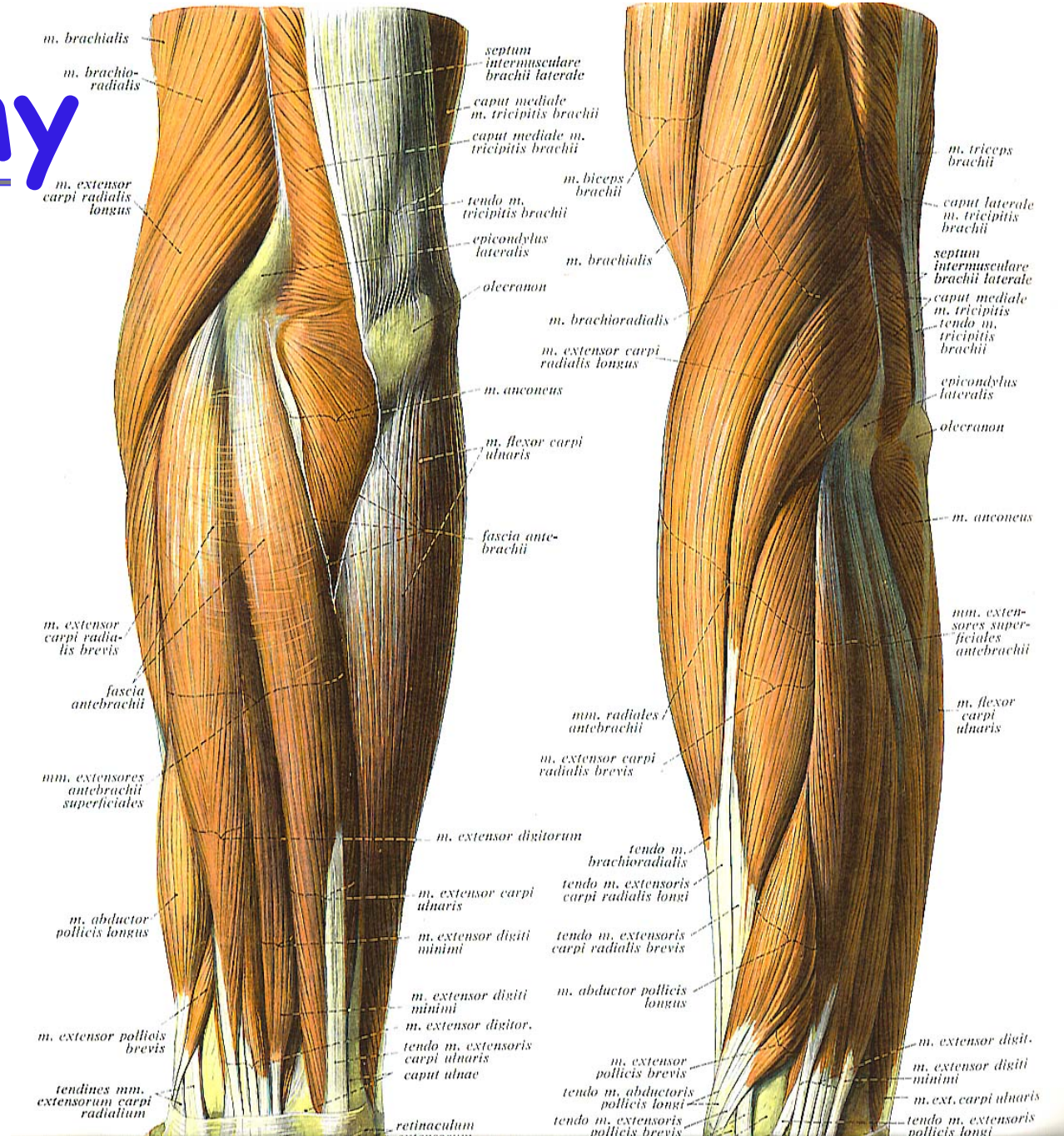
Anterior view



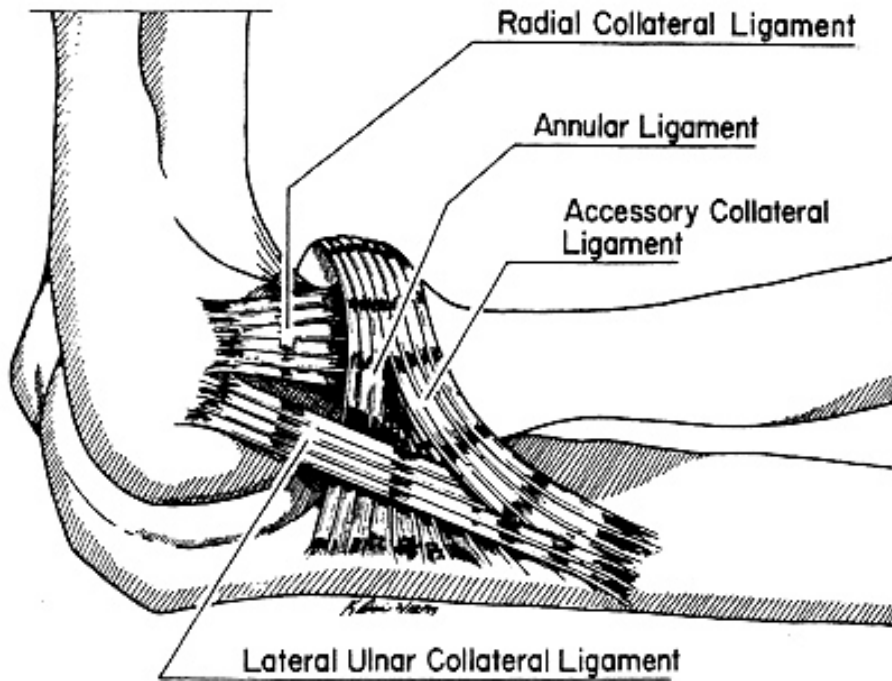
i superficiel des muscles l'avant-bras et m. bra-

Anatomy

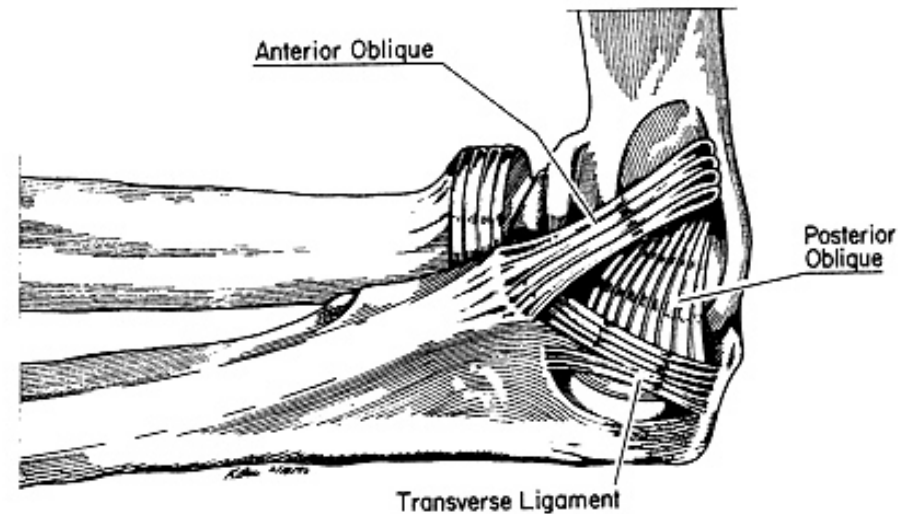
Posterior and Lateral



Anatomy

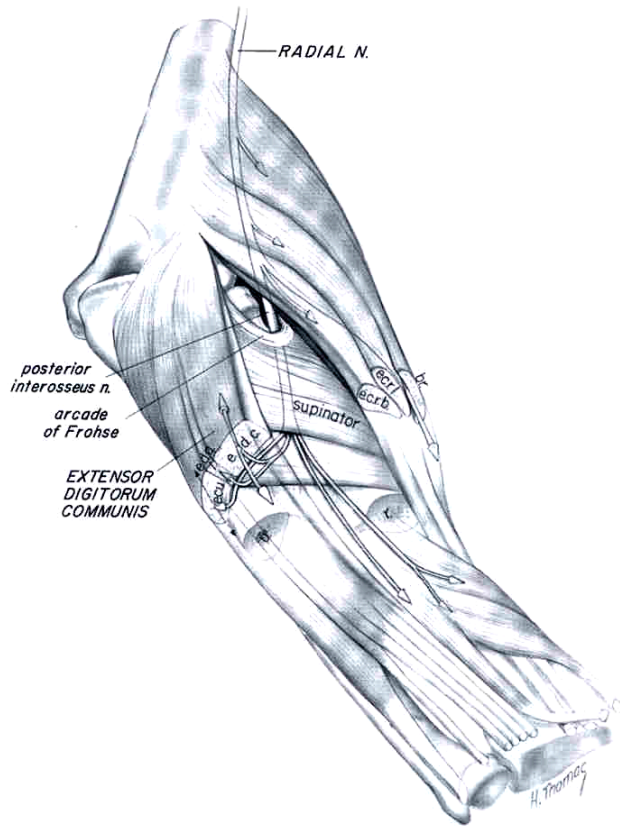


Lateral

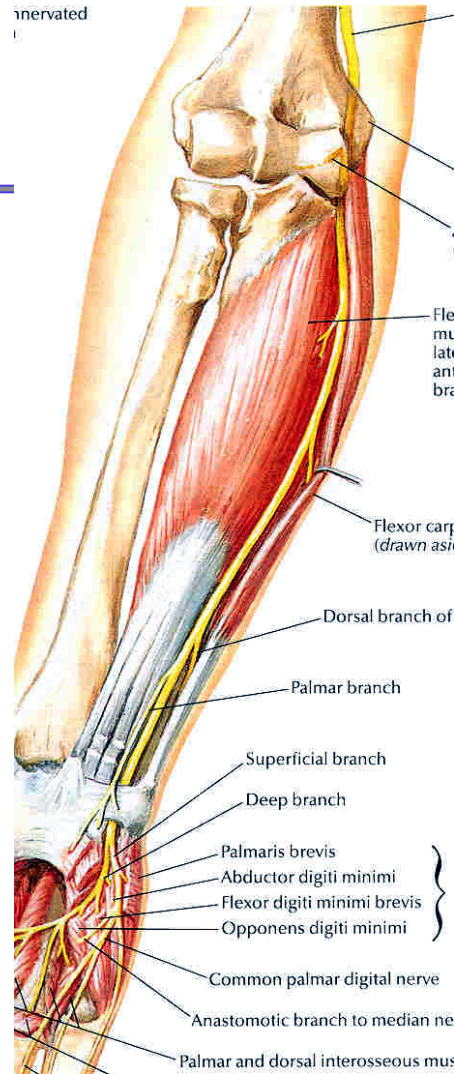


Medial

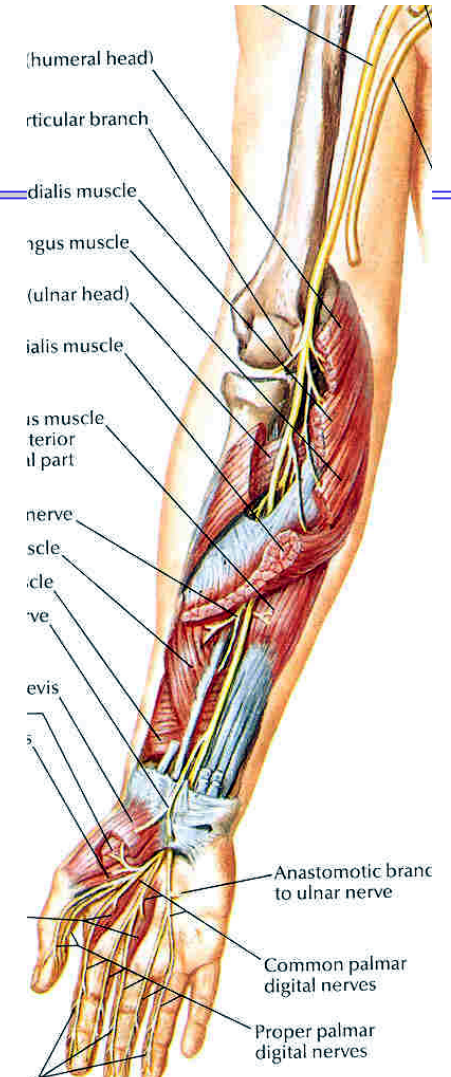
Anatomy



Radial n.



Ulnar n.



Median n.



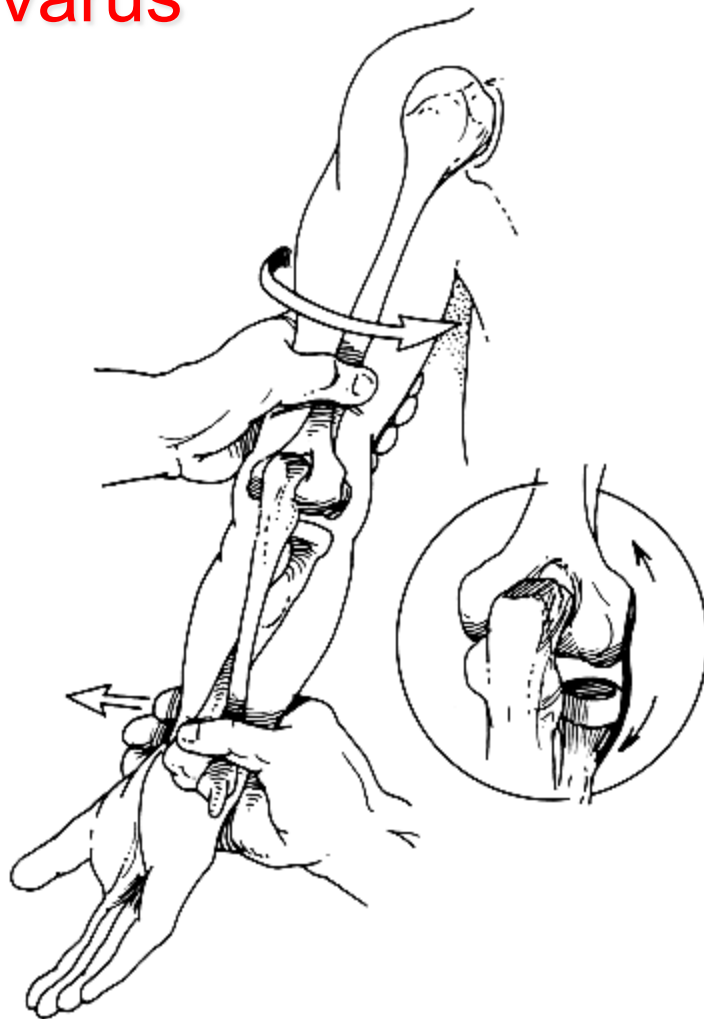
Clinical examination

- ROM
- Palpation
- Stability

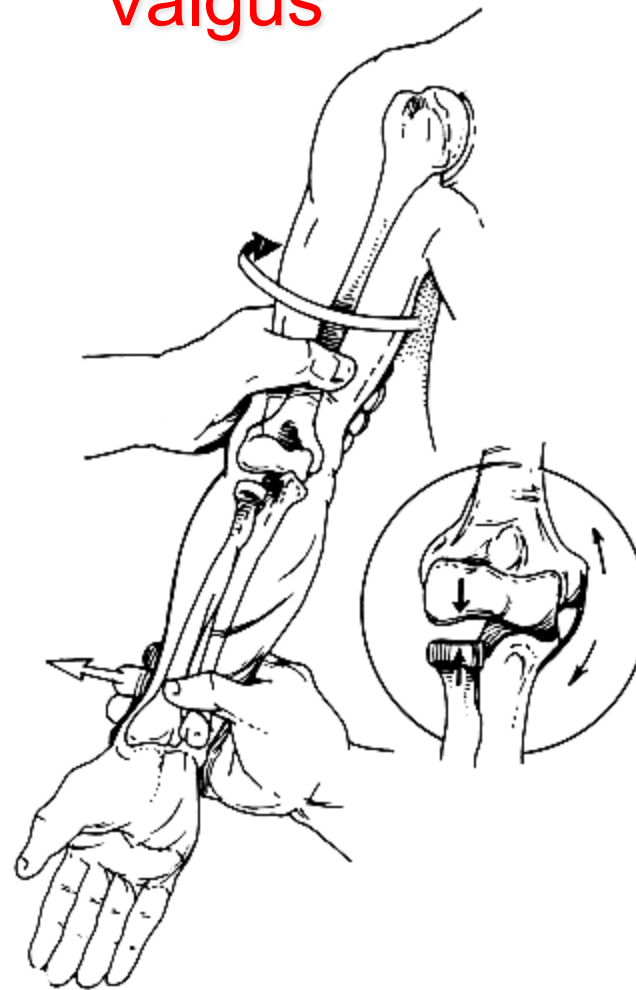
- Provocative test

Stability

Varus

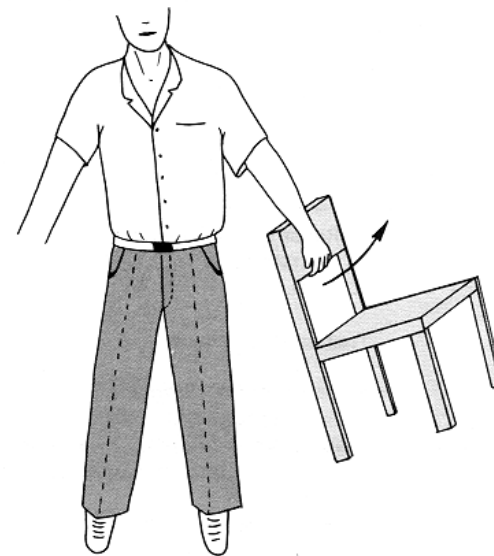
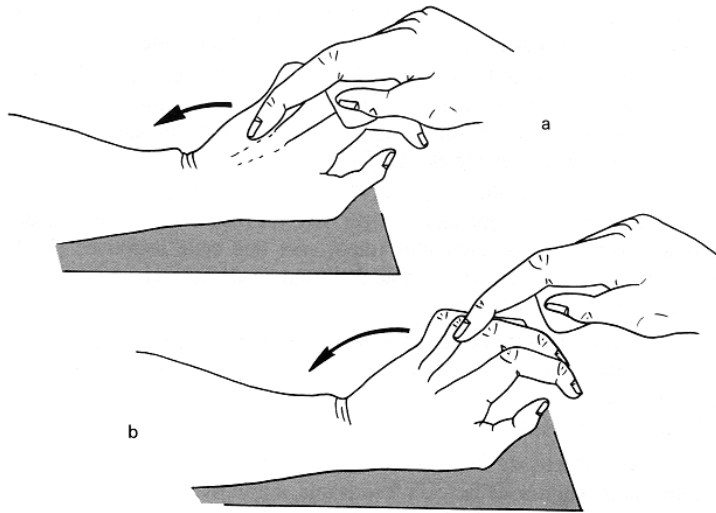


Valgus



Lateral epicondylopathy test

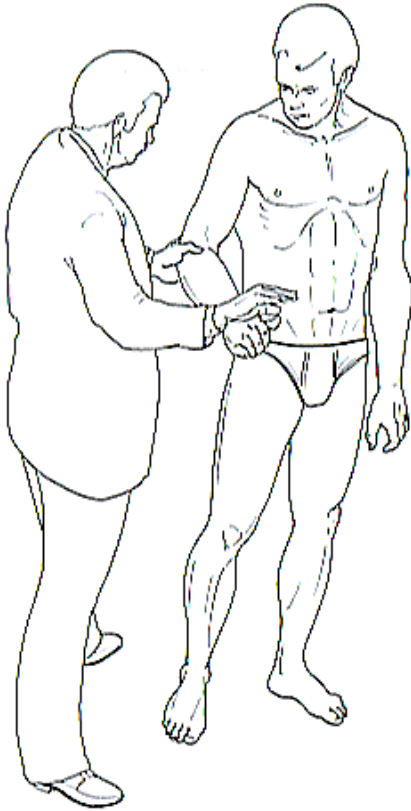
- Extension against resistance of the wrist
- Extension against resistance of the major finger
- Stretching of the extensor digitorum



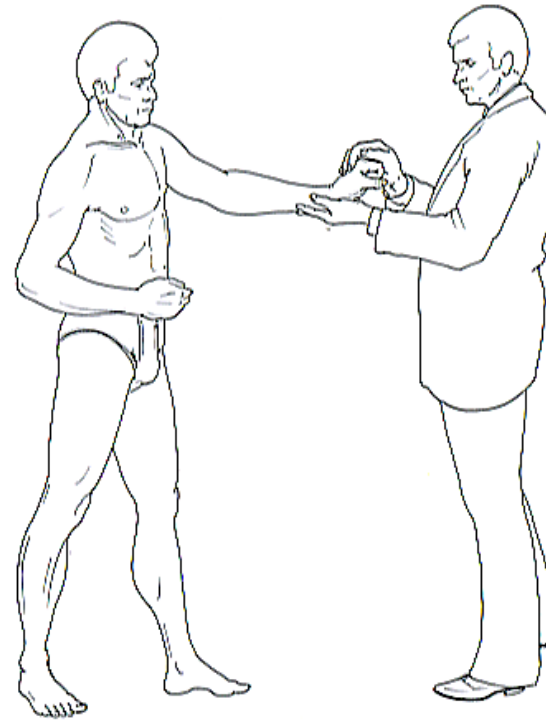
Chair test

Lateral epicondylopathy test

Mill test

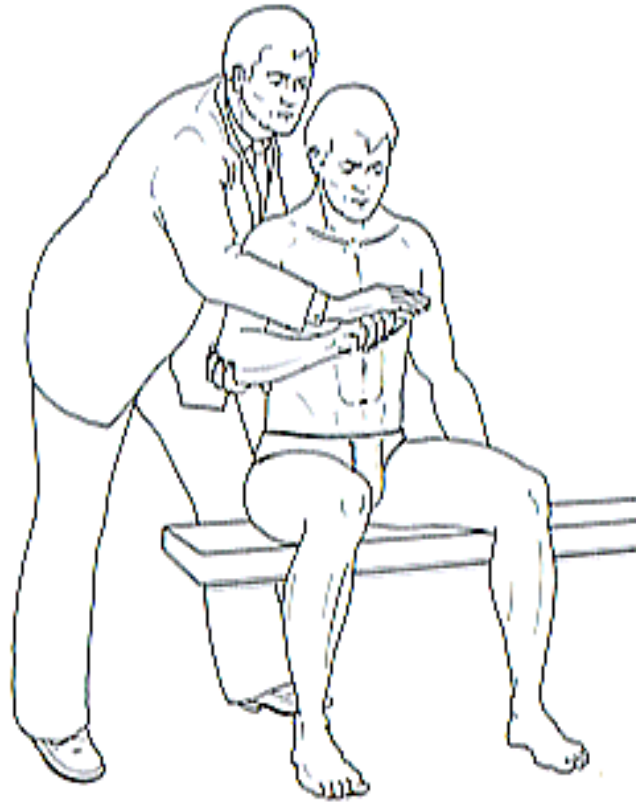

Thompson test



Lateral epicondylopathy test

Cozen test



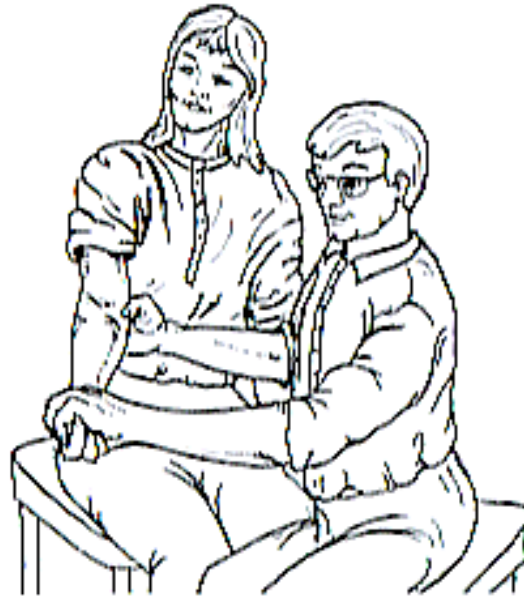Lateral epicondylopathy test



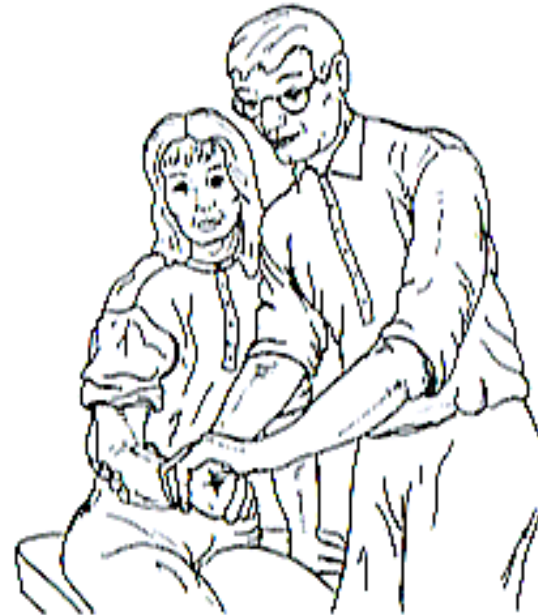Motion stress test:
a starting position,
b extension and
pronation

Medial epicondylopathy test

Reverse Cozen test



a



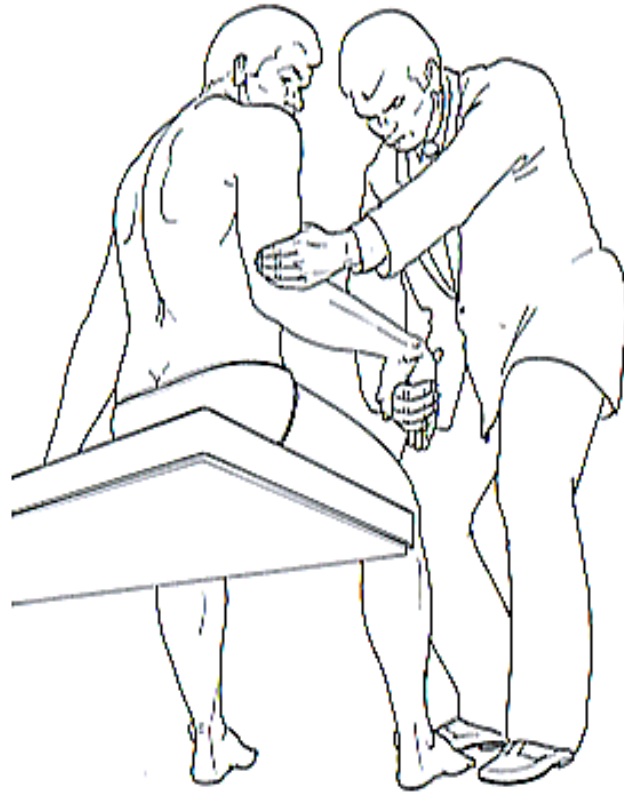
b

Reverse Cozen test:

- a starting position,
- b flexion in the wrist against the resistance of the examiner's hand

Medial epicondylopathy test

Golfer's elbow sign



Golfer's elbow sign

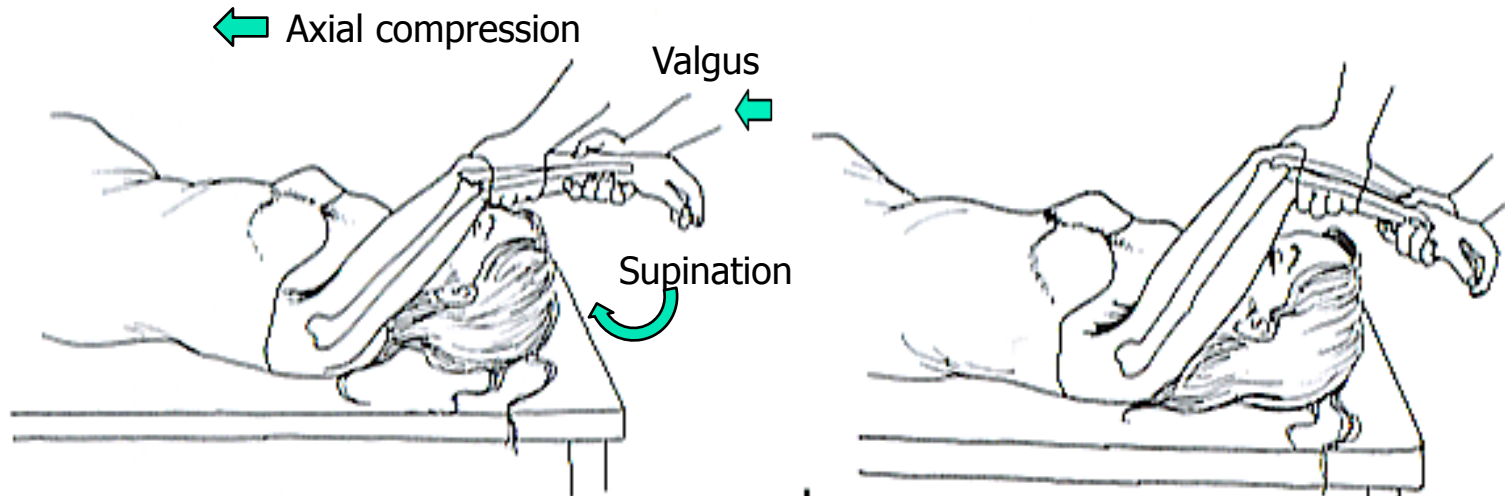
Forearm extension test



Forearm extension test

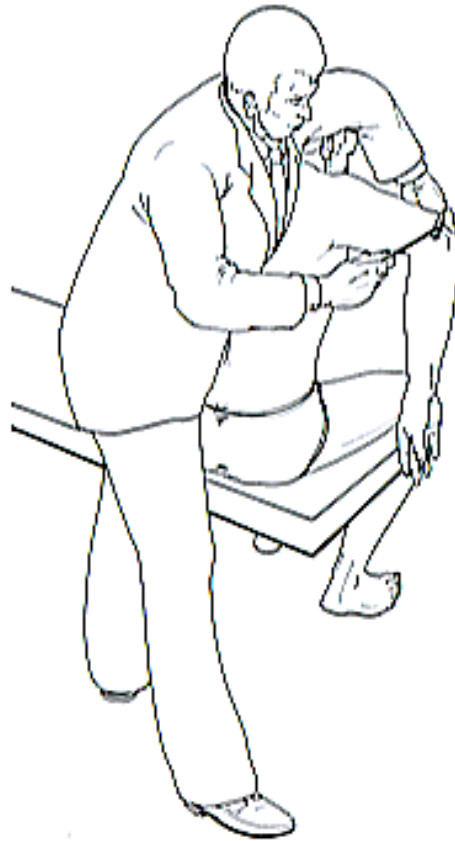Pivot-shift test

Postero-lateral rotatory instability



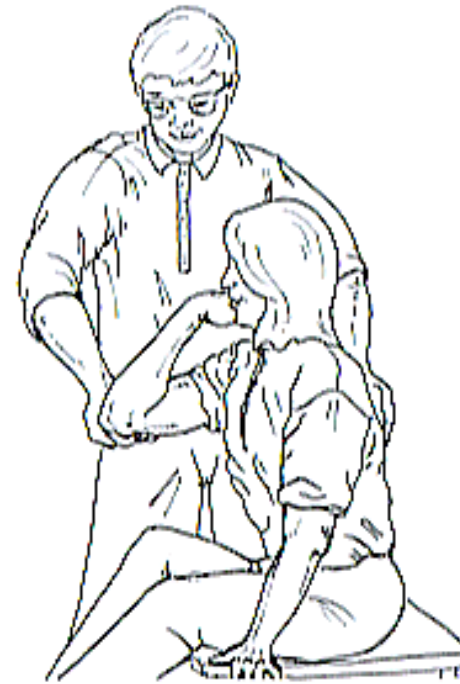Ulnar nerve test

Tinel test



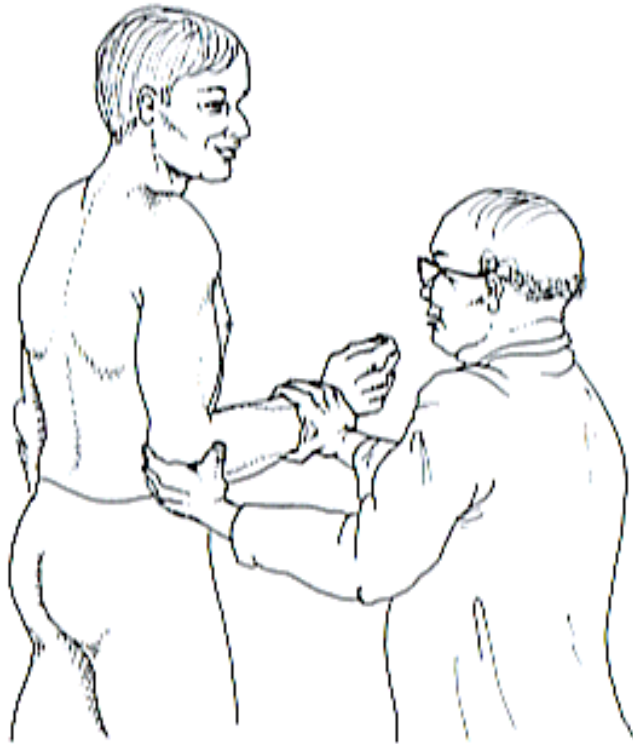
Tinel test

Elbow flexion test



Elbow flexion test

Post interosseous nerve




Supinator compression test


swiss
olympic
medical center


UNITÉ D'ORTHOPÉDIE ET DE TRAUMATOLOGIE DU SPORT

Thank you for your attention



HUG  
Hôpitaux Universitaires de Genève


UNIVERSITÉ DE GENÈVE
FACULTÉ DE MÉDECINE